

Electrograms of a localized source perpetuating Atrial Fibrillation ;

Example of dynamic changes in electrograms during AF revolutions

Julien Seitz, MD; Alexandre Maluski, MD; Ange Ferracci, MD;
Laurence Curel, MS; Michel Bremondy, MD; Jacques Faure, MD and
André Pisapia, MD.

HOPITAL SAINT JOSEPH, MARSEILLE, France

Disclosures

Speaker fees and honoraria as a consultant (minors) from Biosense Webster, St Jude Medical, Medtronic, Boehringer Ingelheim.

Case presentation

- A 41-year-old man with symptomatic drug-refractory paroxysmal AF
- referred for a new catheter ablation procedure 6 months after a first one because of AF recurrences.
- Previous ablation : circumferential PVI

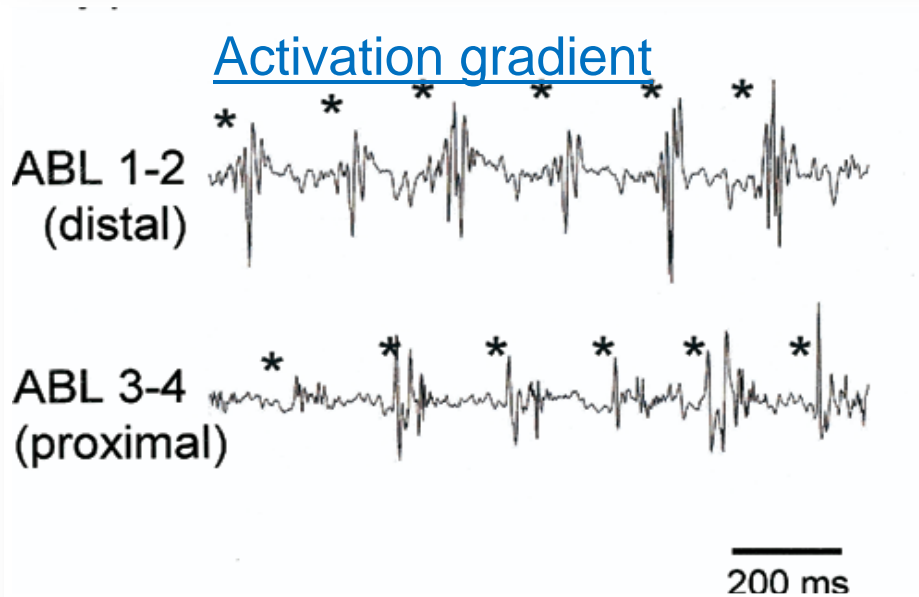
Ablation procedure strategy

- AF induced at the beginning
- **EGM-based substrate Ablation**
 - ➔ primary targeted EGMs:

1



2

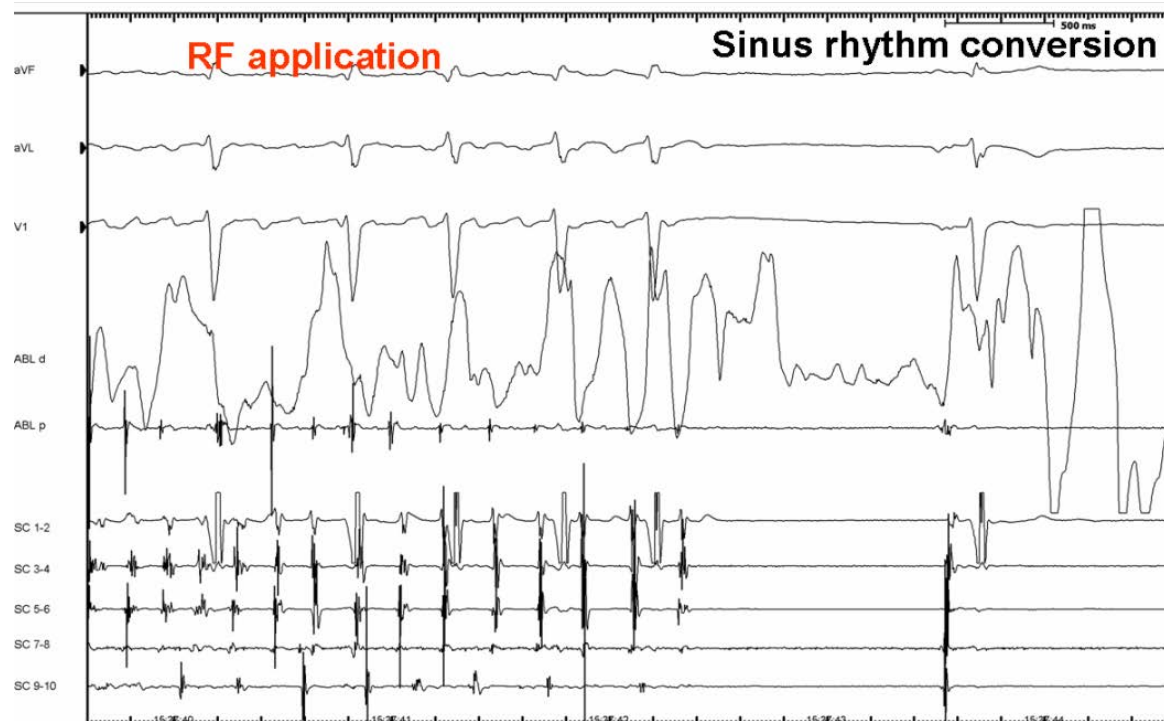
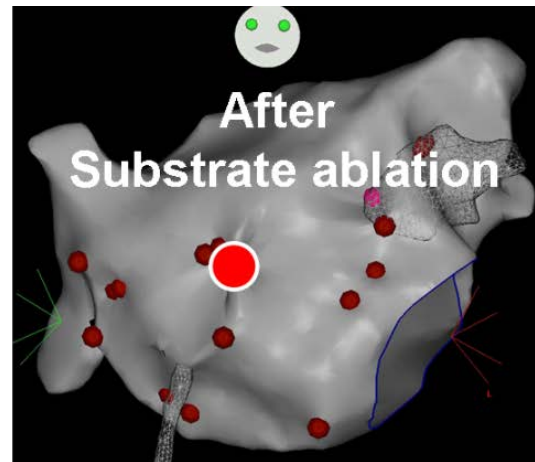


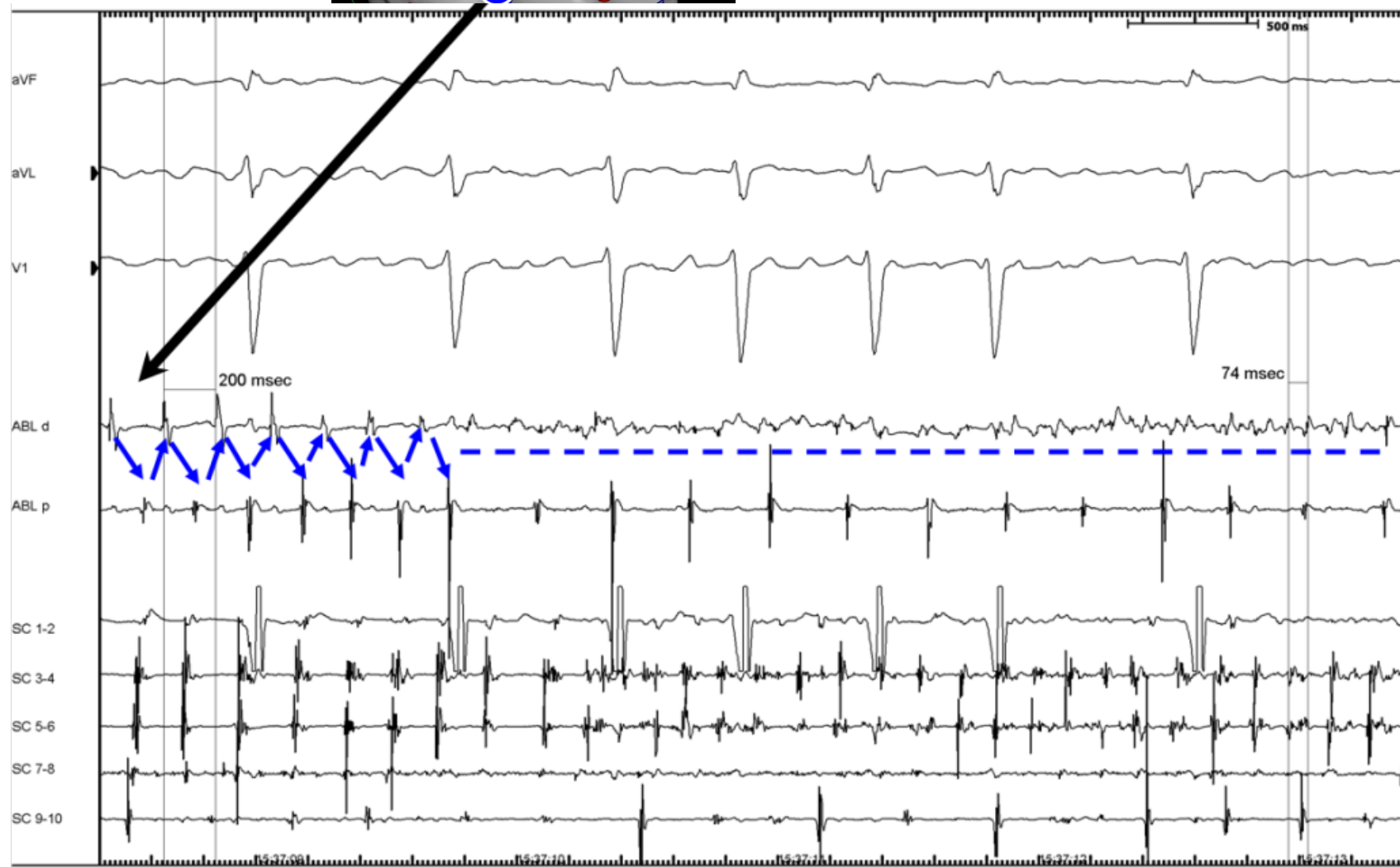
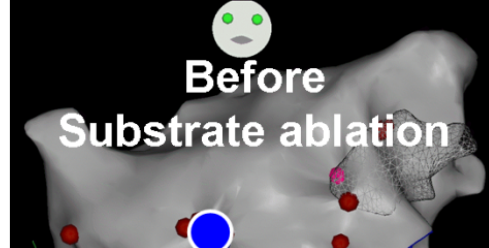1. Nademanee et al. JACC 2004

1&2. Takahashi et al. JACC 2008

CRUCIAL POINT = AF TERMINATION

- Point by point RF applications (15-45Wtt)
- Crucial area : anterior LA wall



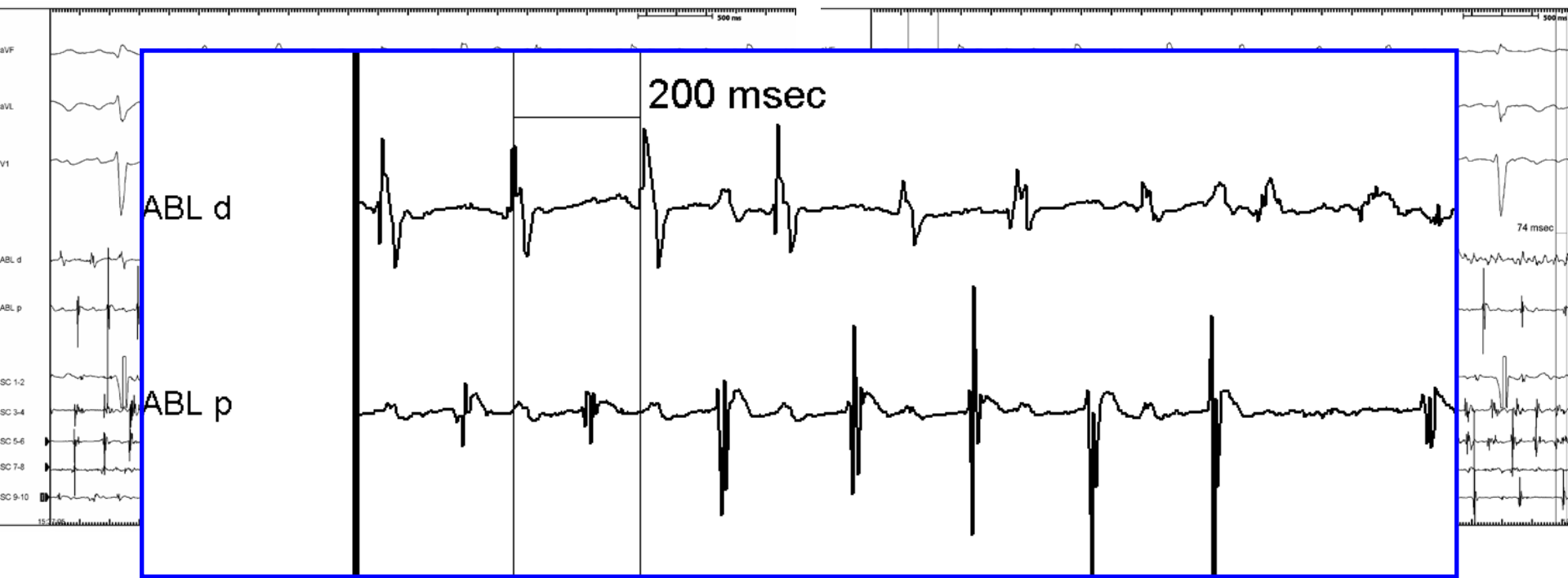

↕ Temporal gradient of activation

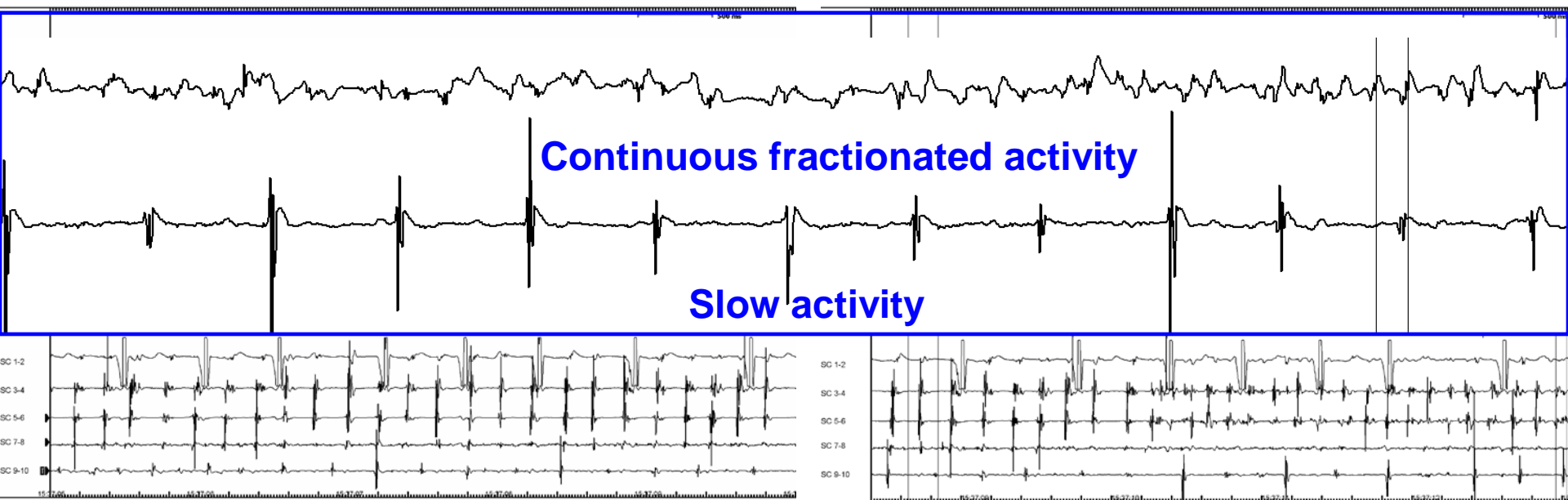
— CFAE (continuous activity)

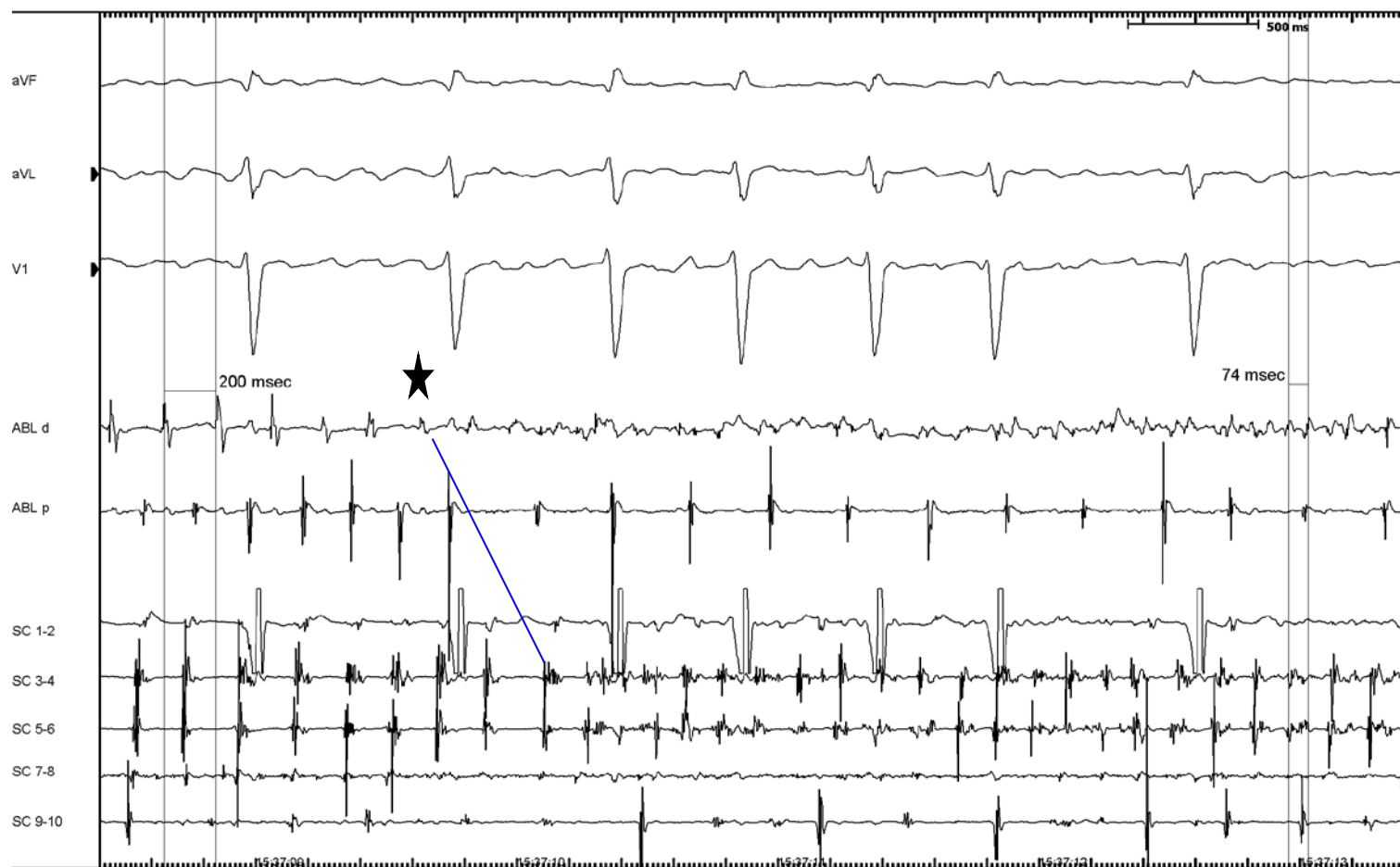
What is our interpretation of these
EGMs?

Micro Re-entry or a conduction block?

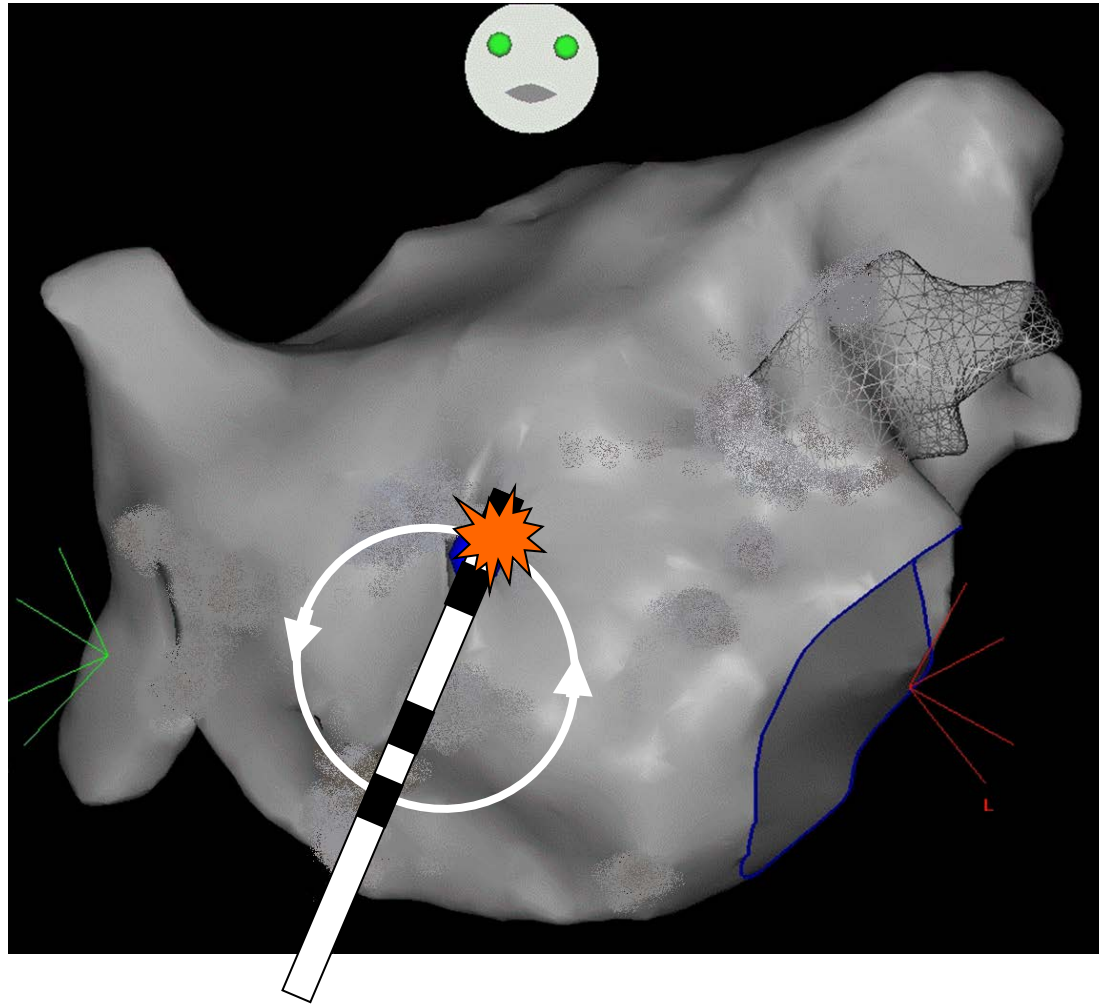


Non monomorphic EGMs

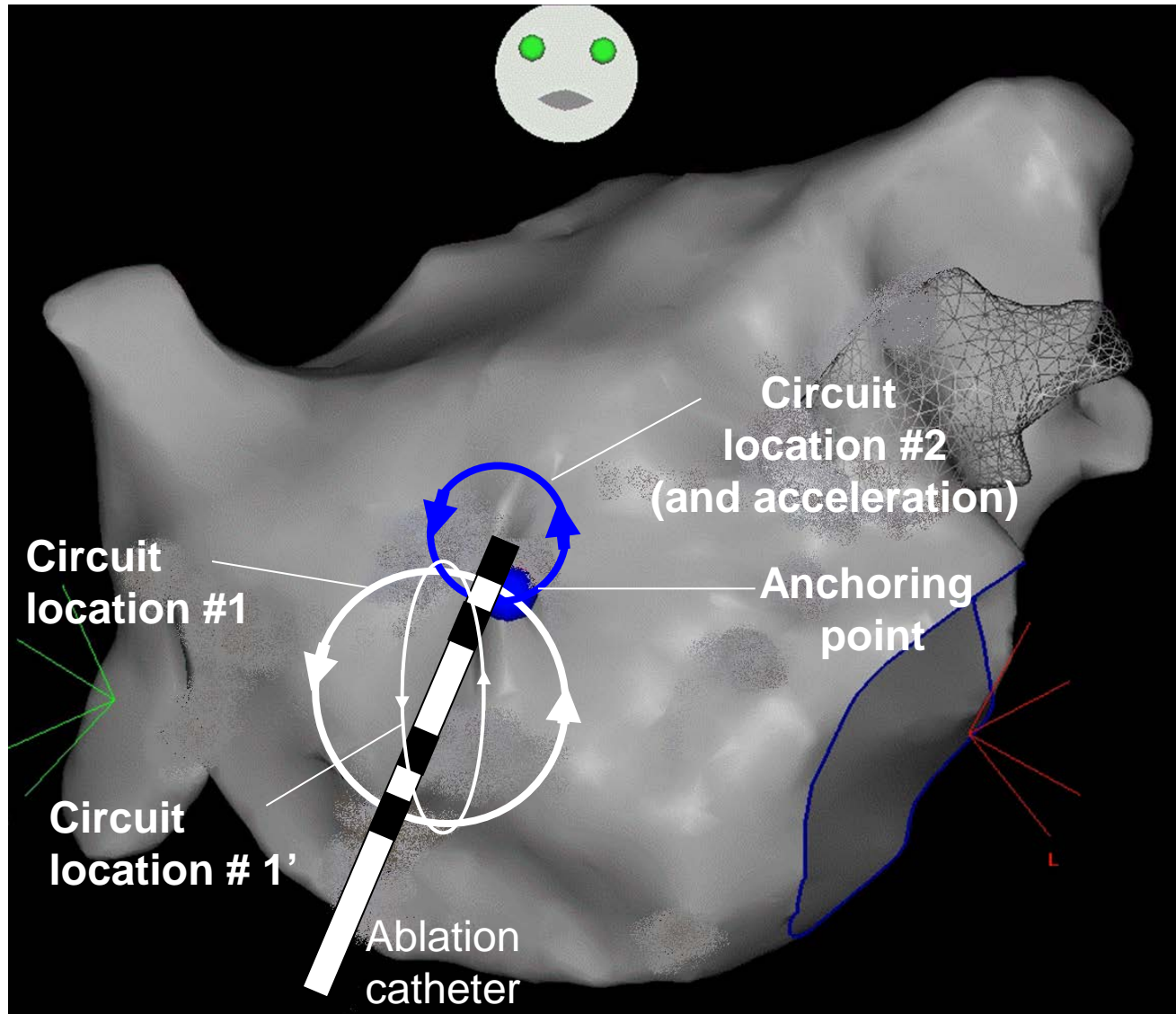




Micro re-entry + Focal Rapid Activity?



Drifting and acceleration of and anchored re-entry (rotor)?



Conclusion

- Good example of AF substrate outside the PV region in a paroxysmal AF
- We showed the EGMs of a crucial area involved in AF perpetuation
- We believe that these EGMs correspond to a 3D drifting & accelerating microentry otherwise known as a ROTOR.

Thank you for your attention

A photograph of a modern building at night. The building has a large section with a facade made of many small, glowing blue lights, creating a starry or pixelated effect. To the right, there is a section with large glass windows that are brightly lit from within, showing interior spaces. The building is situated on a platform or pier over a body of water, and the blue lights from the facade are reflected in the water's surface. The sky is dark blue.

Julien Seitz, MD; Alexandre Maluski, MD; Ange Ferracci, MD;
Laurence Curel, MS; Michel Bremondy, MD; Jacques Faure, MD
and André Pisapia, MD.

HOPITAL SAINT JOSEPH, MARSEILLE, France