



TURIN, 20<sup>TH</sup>—21<sup>ST</sup> NOVEMBER 2008

# GREAT INNOVATIONS IN CARDIOLOGY

4<sup>TH</sup> JOINT MEETING WITH MAYO CLINIC

4<sup>TH</sup> TURIN CARDIOVASCULAR NURSING CONVENTION



ABSTRACT SESSION (PART I)

Chairmen

**F. Bertello (Torino), M. Sicuro (Aosta)**



**“APICAL BALLOONING” CARDIOMIOPATIA ACUTA DA  
STRESS REVERSIBILE :  
LA NOSTRA ESPERIENZA DI DUE ANNI**

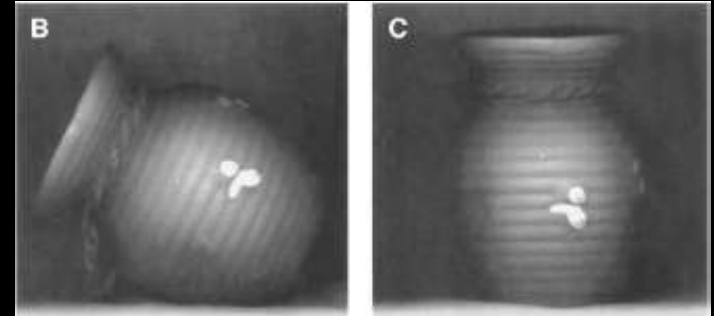
A. Andria, M. Anselmino, S. Colangelo, O.Pallisco, G.  
Boccuzzi, R. Garbo, P.Lusardi, A.Bellone, P. Noussan, M.  
Minelli

Dipartimento di Cardiologia  
Ospedale San Giovanni Bosco Torino



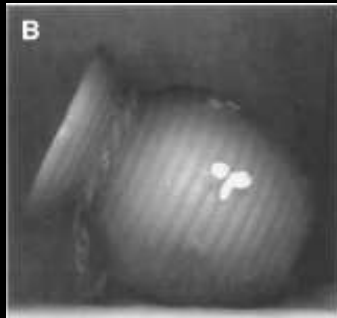
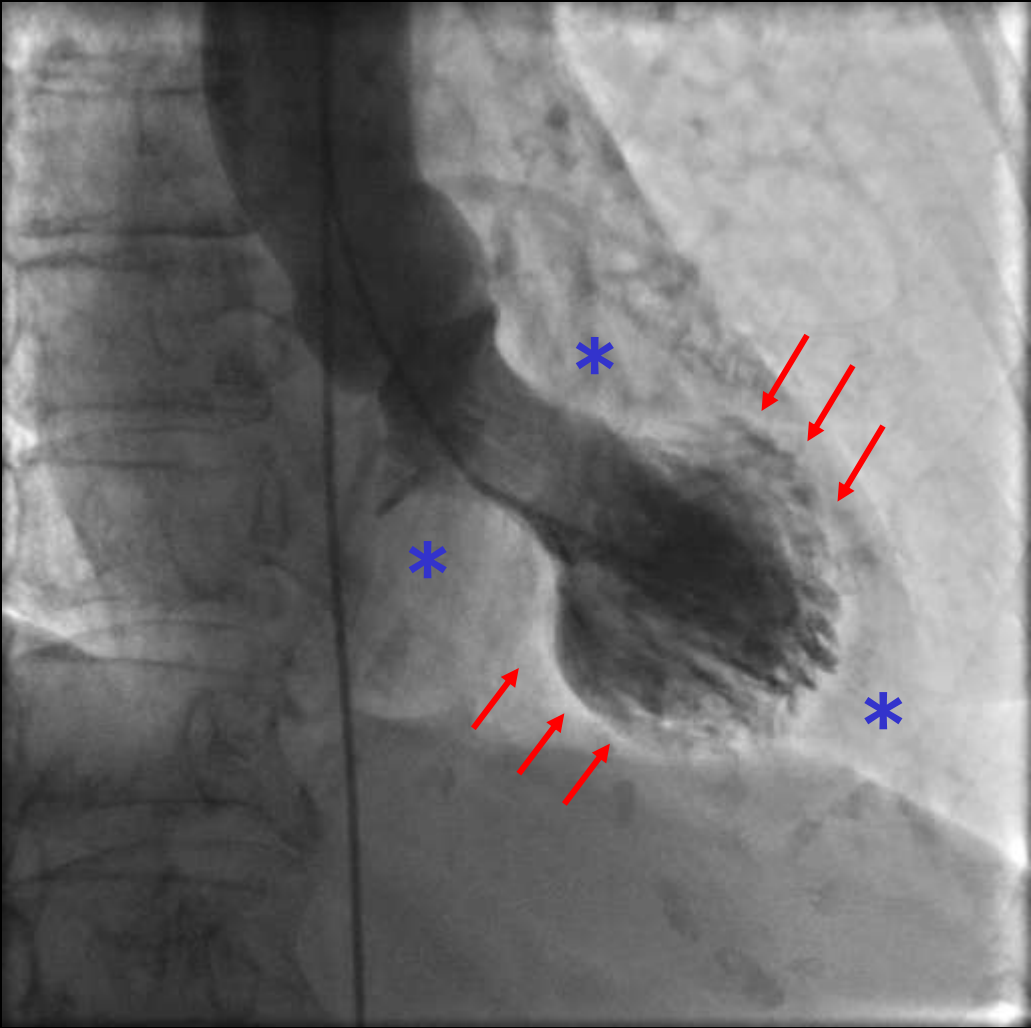
# Background

*tako-tsubo*



The cardiac syndrome known as *tako-tsubo* or transient left ventricular dysfunction has been recognized recently as a novel entity within the spectrum of **acute coronary syndromes (ACS)**

# Left ventriculogram



## PROPOSED MAYO CLINIC CRITERIA FOR ABS

1. Transient hypokinesia, akinesia or dyskinesia of the left ventricular mid segments with or without apical involvement.  
A stressful trigger is often, but not always present.
2. No significant stenosis on coronary angiography
3. New electrocardiographic abnormalities (ST-segment elevation/T-wave inversion) or modest elevation in cardiac troponin.

# PROPOSED MAYO CLINIC CRITERIA FOR ABS

## 4. Absence of :

- a. Pheochromocytoma
- b. Myocarditis

# PATHOPHYSIOLOGY

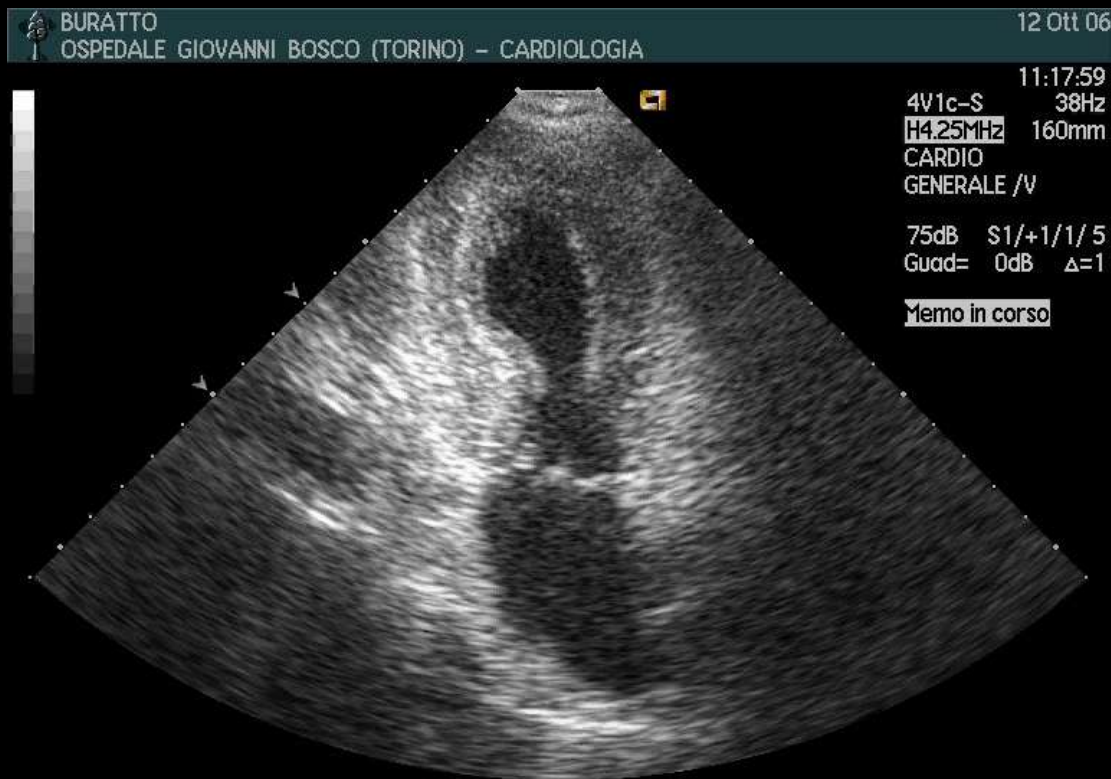
- **Catecholamine-induced myocardial stunning**
- **Ischemia-mediated stunning due to multivessel epicardial or microvascular spasm**
- **Dysfunctional metabolism of cardiomyocytes**
- **myocarditis**



# Transthoracic echocardiogram

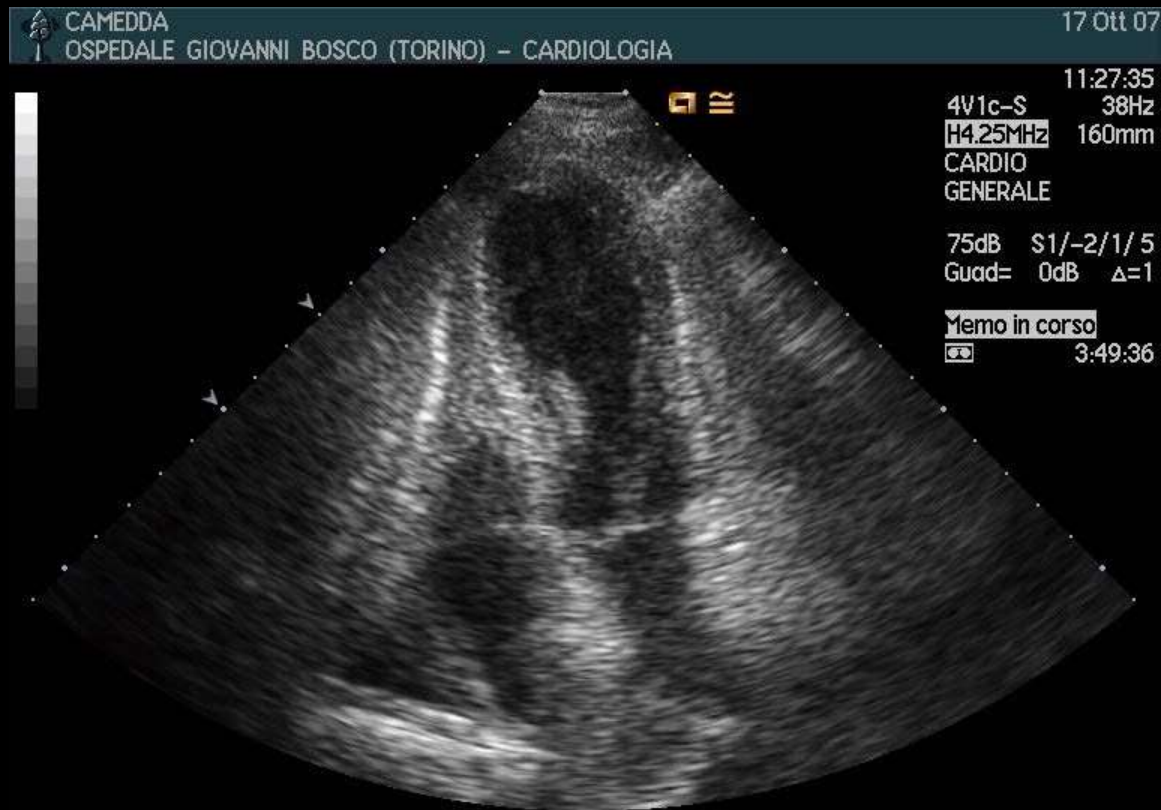
ECO TT showed: Dilatation and akinesis of the midventricle with hypercontractile apex and base (Ejection fraction:50%).

## The apical 2-chamber view





# Transthoracic echocardiogram



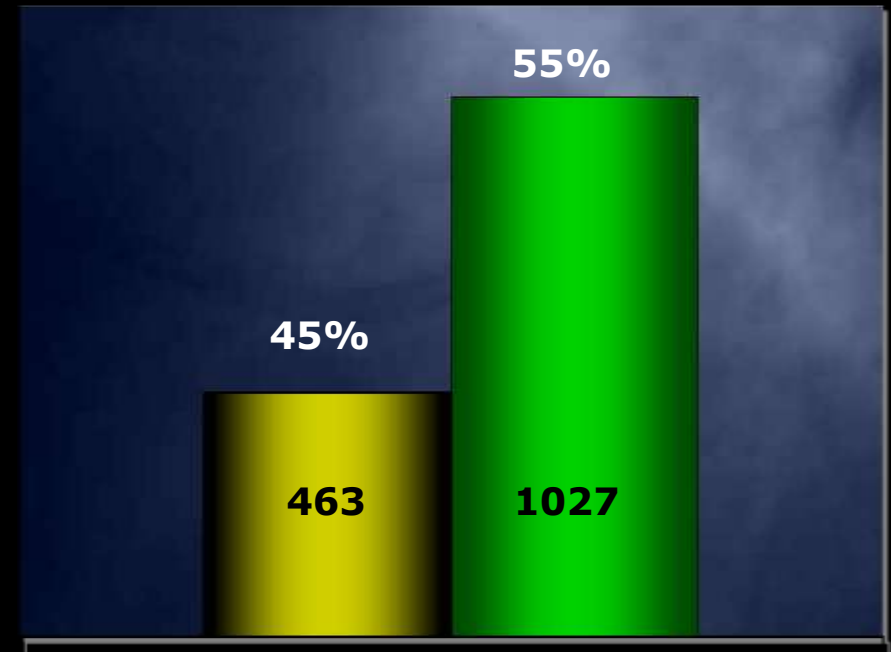
# Methods

From January 2006 to September 2008  
we included

1490 patients admitted to our Hospital  
for ACS

All patients underwent urgent coronary  
angiography

The patients were divided in two groups  
based on ST-segment elevation:



**GROUP 1**



ST-segment elevation myocardial infarction

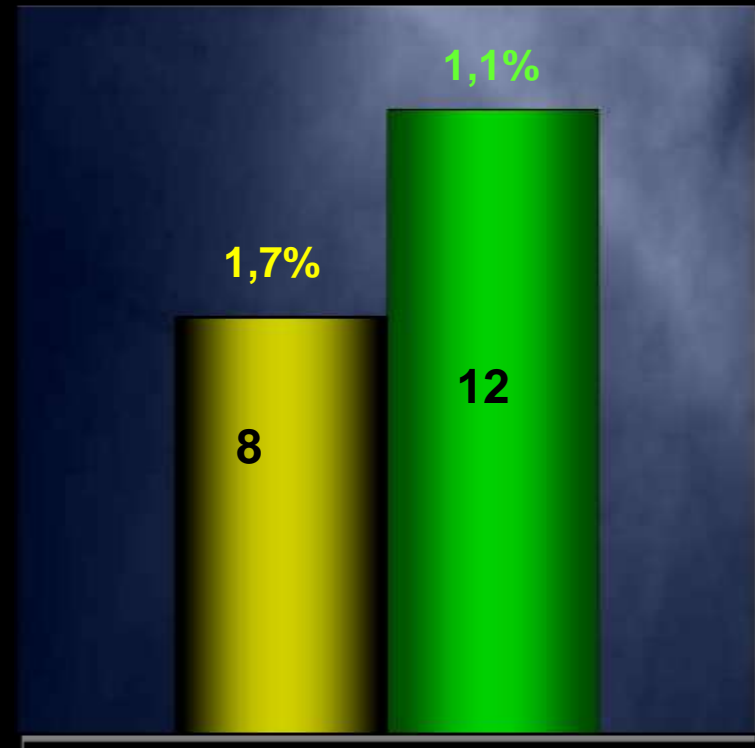
**GROUP 2**



non-ST segment elevation ACS

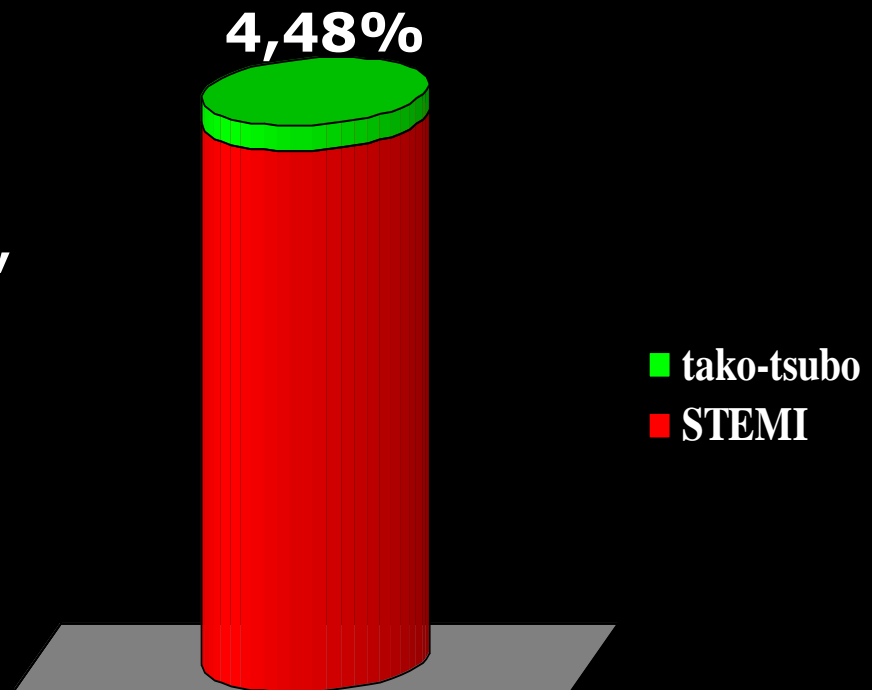
# Results

- **Tako-Tsubo** cardiomyopathy was identified in **20** (18 women, 2 men) of all investigated patients with a frequency of **1.3%**
- **Tako-tsubo** with T-segment elevation patients was identified in **8** patients (**1,7%** of **STEMI**), non ST-segment elevation in **10** patients( **1,1%** of **NSTEMI**)



## RISULTATI

156 donne presentavano un quadro ECG di STEMI, in 7 paz (4,48%) è stata fatta diagnosi di ABS in base al quadro angiografico ed ecocardiografico.



# CARATTERISTICHE CLINICHE

		<i>n=20</i>
età (anni)		66±10
sexo (M/F)		2/20
FdR	tabagismo [n (%)]	4(20)
	ipertensione arteriosa [n (%)]	13 (65)
	diabete mellito [n (%)]	1 (4)
	ipercolesterolemia [n(%)]	5 (25)
	familiarità [n (%)]	4 (17)

## SINTOMATOLOGIA D'ESORDIO

*n=20*

dolore toracico [n (%)]	18 (90)
dispnea [n (%)]	6 (30)
lipotimia/sincope [n (%)]	2(10)

*n=20*

Trop. T (ng/ml)	0.83±0.57
-----------------	-----------

## EVENTO STRESSOGENO SCATENANTE

**14** pazienti **70%**

**stress fisico**

**n=4** 20%

**stress psichico**

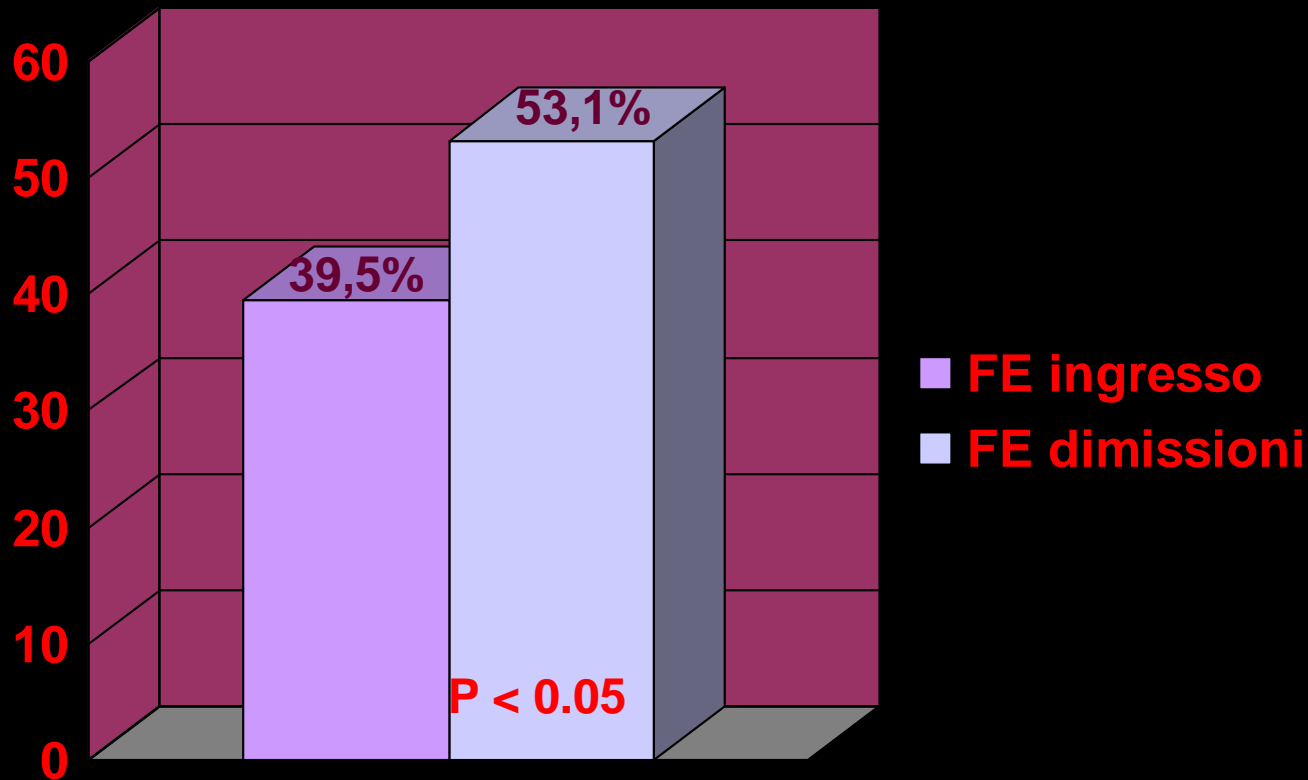
**11** 55%

## CARATTERISTICHE ECO

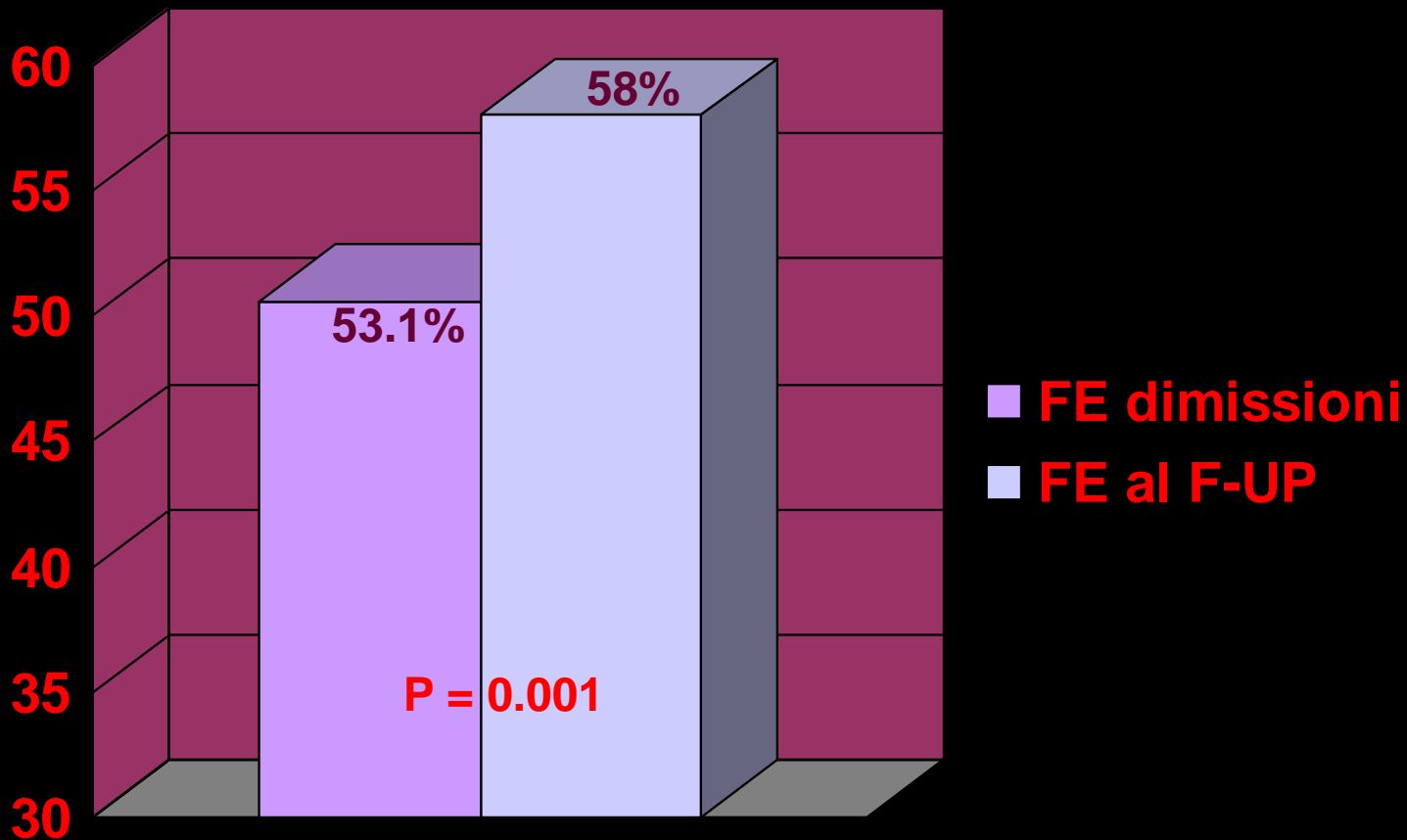
	<i>fase acuta</i>	<i>dimissione</i>
FE (%)	<i>n=20</i> 39±8	<i>n=19/20 (95%)</i> 53±7
gradiente V Sin [n(%)]	1 (4) 30 mmHg	8 mmHg
FE (%)		<i>Follow-up</i> <i>n=17/20 (85%)</i> 58±4



# Valori della frazione di eiezione all' ingresso ed alla dimissione



# Valori della frazione di eiezione alla dimissione ed al follow-up



# Transthoracic echocardiogram

BURATTO  
OSPEDALE GIOVANNI BOSCO (TORINO) - CARDIOLOGIA


13 Nov 07

14:17:42

4V1c-S 38Hz  
H3.75MHz 160mm  
CARDIO  
GENERALE /V

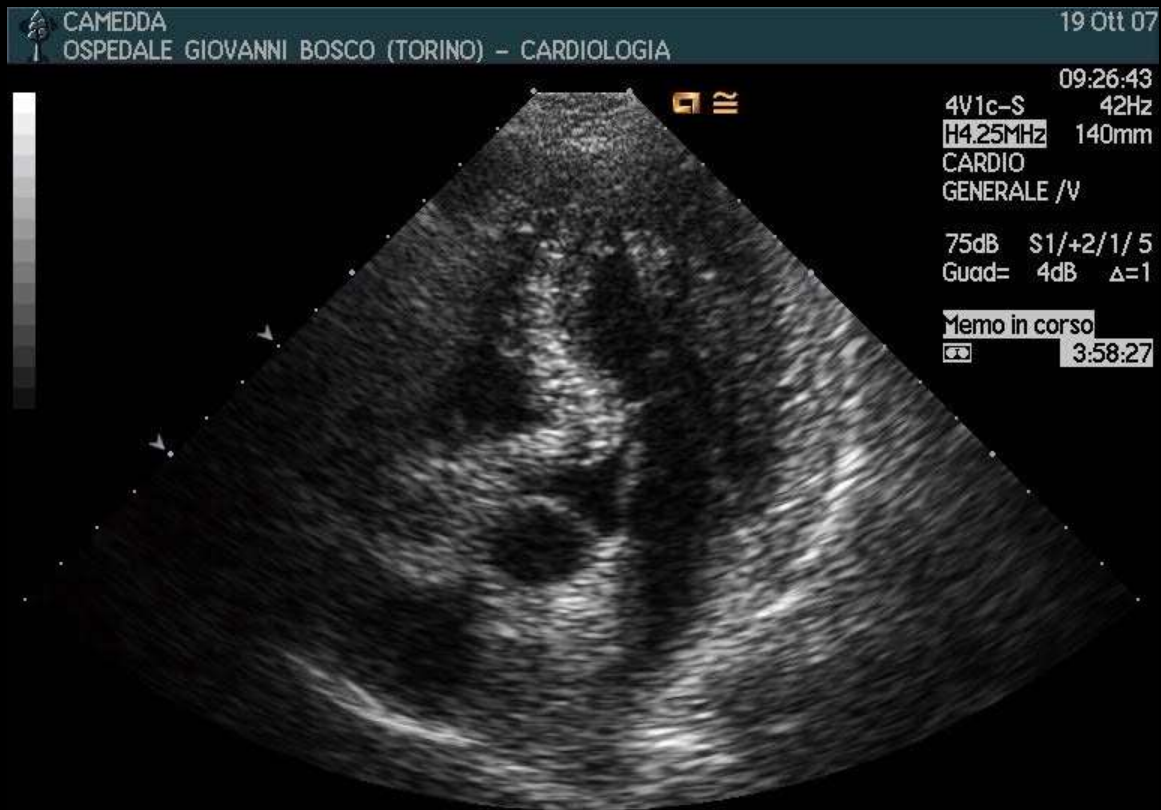72dB S1/+2/1/ 5  
Guad= 4dB Δ=1

Memo in corso  
6:51:55



Stampa in corso...

# Transthoracic echocardiogram



# casistica: eventi

	<i>intra-osp</i>	<i>follow-up</i> 14 mesi +/-8(media)
	<b>n=20</b>	<b>n=19/20 (95%)</b>
decesso [n (%)]	0	0
<b>COMPLICANZE MAGGIORI [n (%)]</b>		
insuff ventricolare sinistra [n (%)]	2 (8)	0
bradiaritmia (BAV III° transitorio) [n (%)]	1 (4)	
<b>COMPLICANZE MINORI [n (%)]</b>		
sanguinamento	1 (4)	
insuff mitralica moderata	1 (4)	
ostruzione dinamica tratto effl.	1 (4)	
<b>RECIDIVA [n (%)]</b>		0
dispnea [n (%)]		1 (4)
precordialgia atipica		1 (4)

# Conclusioni

La sindrome di **Tako-tsubo** va considerata nella diagnosi differenziale con la SCA, spt nelle donne.

Pur essendo caratterizzata all'esordio da un quadro strumentale di importante disfunzione del V SX,  
il decorso si presenta benigno con completa risoluzione a breve.

Questi dati sembrerebbero a favore di un ruolo preponderante del sistema nervoso simpatico.





Grazie per l'attenzione