

Case from Maria Vittoria Hospital

Alessandra Chinaglia, Rita Trincherò

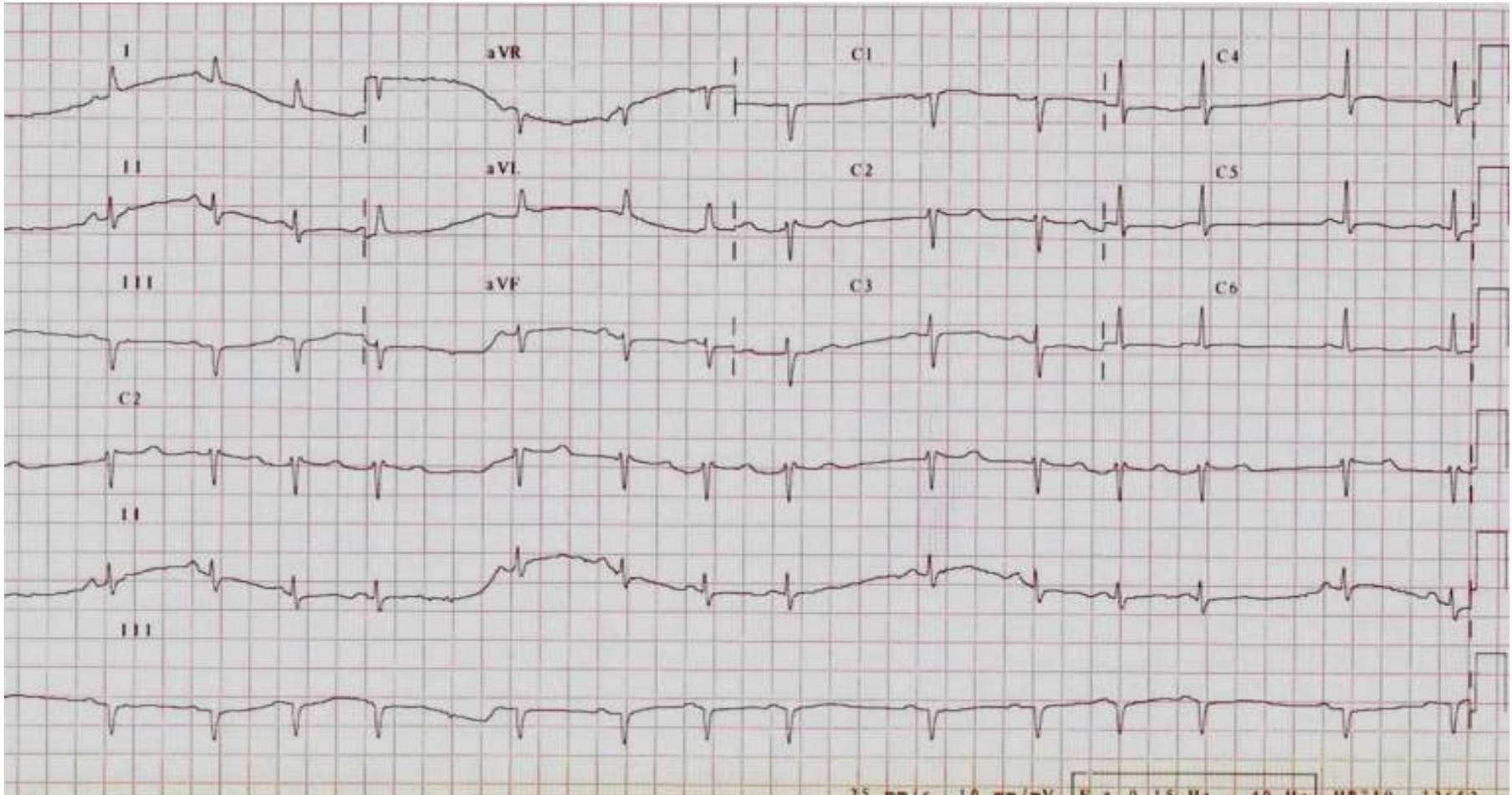
Dipartimento di cardiologia, Ospedale Maria Vittoria
ASLTO2, Torino



- Female, age 57
- Smoking habit
- Mother with myocardial infarction (age 69).
- Since 2002 palpitations treated with sotalol.
- 2007 atrial fibrillation, treated with propafenon (still in therapy). She complained tachycardia mostly in the night.

- 20/10 while she was waiting to ask a question during a conference she complained oppressive chest pain, not irradiated.
- After 2 hours she got to the Emergency Departement.

EKG 21/10



- The pain persisted the whole night; it disappeared spontaneously at 7 o'clock in the morning.

Blood tests

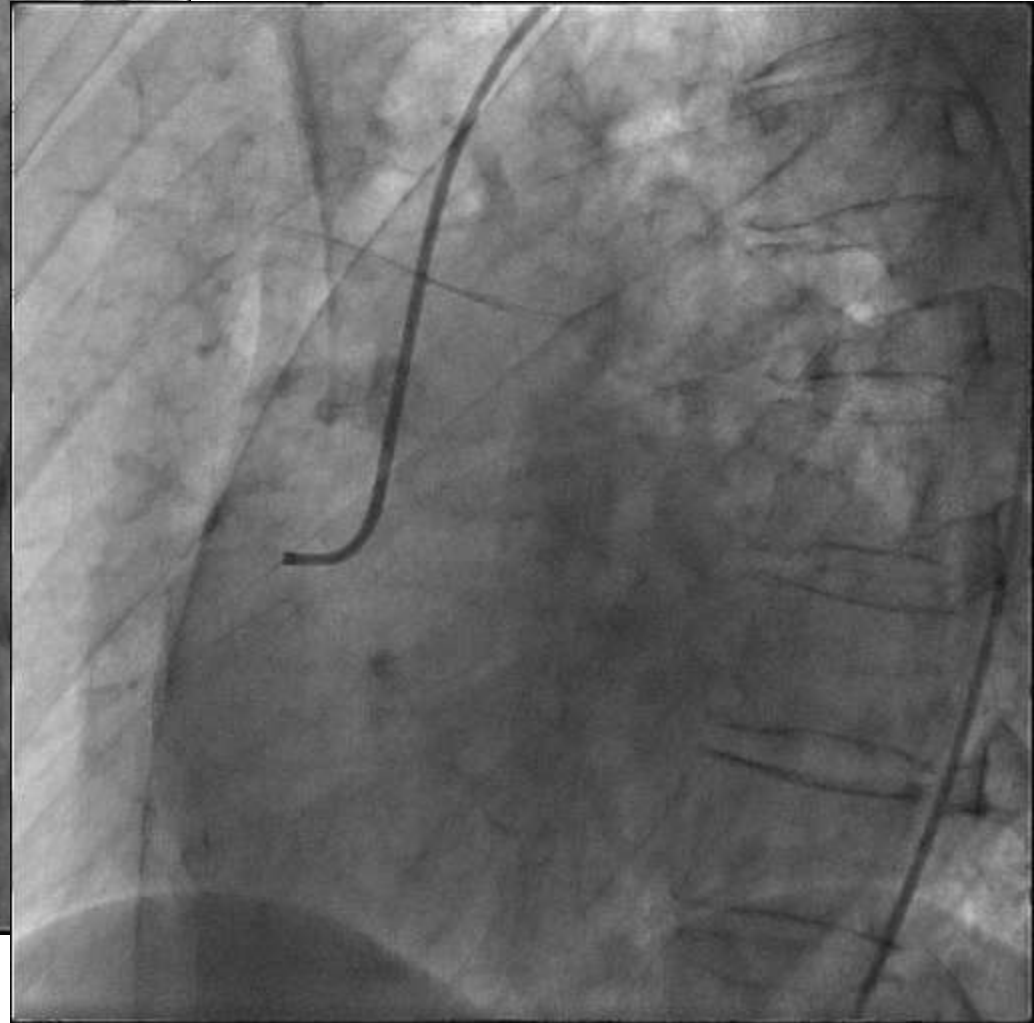
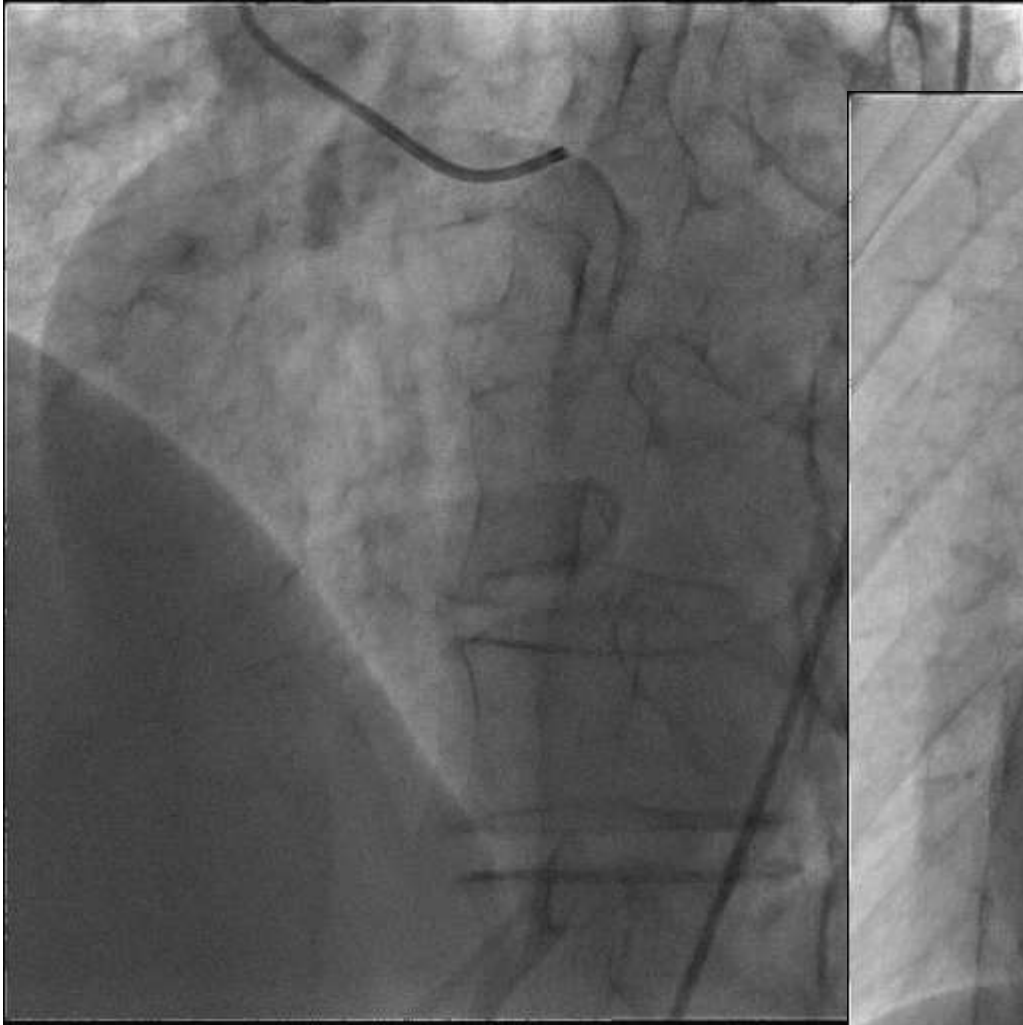
- Troponin I 0.18 → 1.8 → 2.04
- Leucocytes 8.4
- Hemoglobin 12.7
- Platelets 256
- Creatinin 0.7
- High sensitivity C reactive protein 0.04

Echocardiography: apical and anterolateral
diskinesia

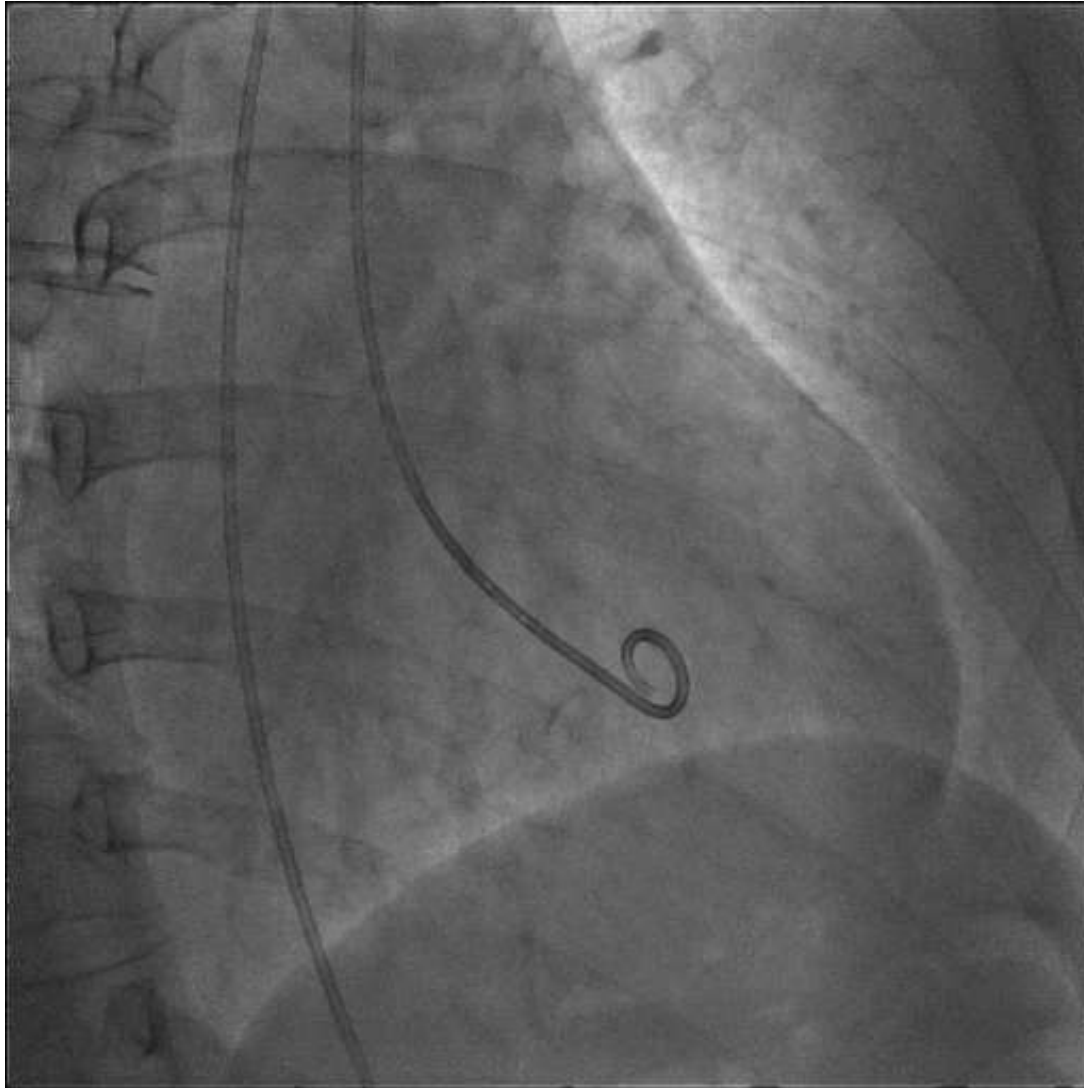
Next step ?

She was transferred for coronary angiography
to Maria Vittoria Hospital

Coronary angiography

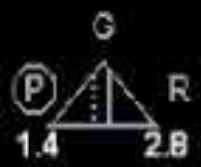
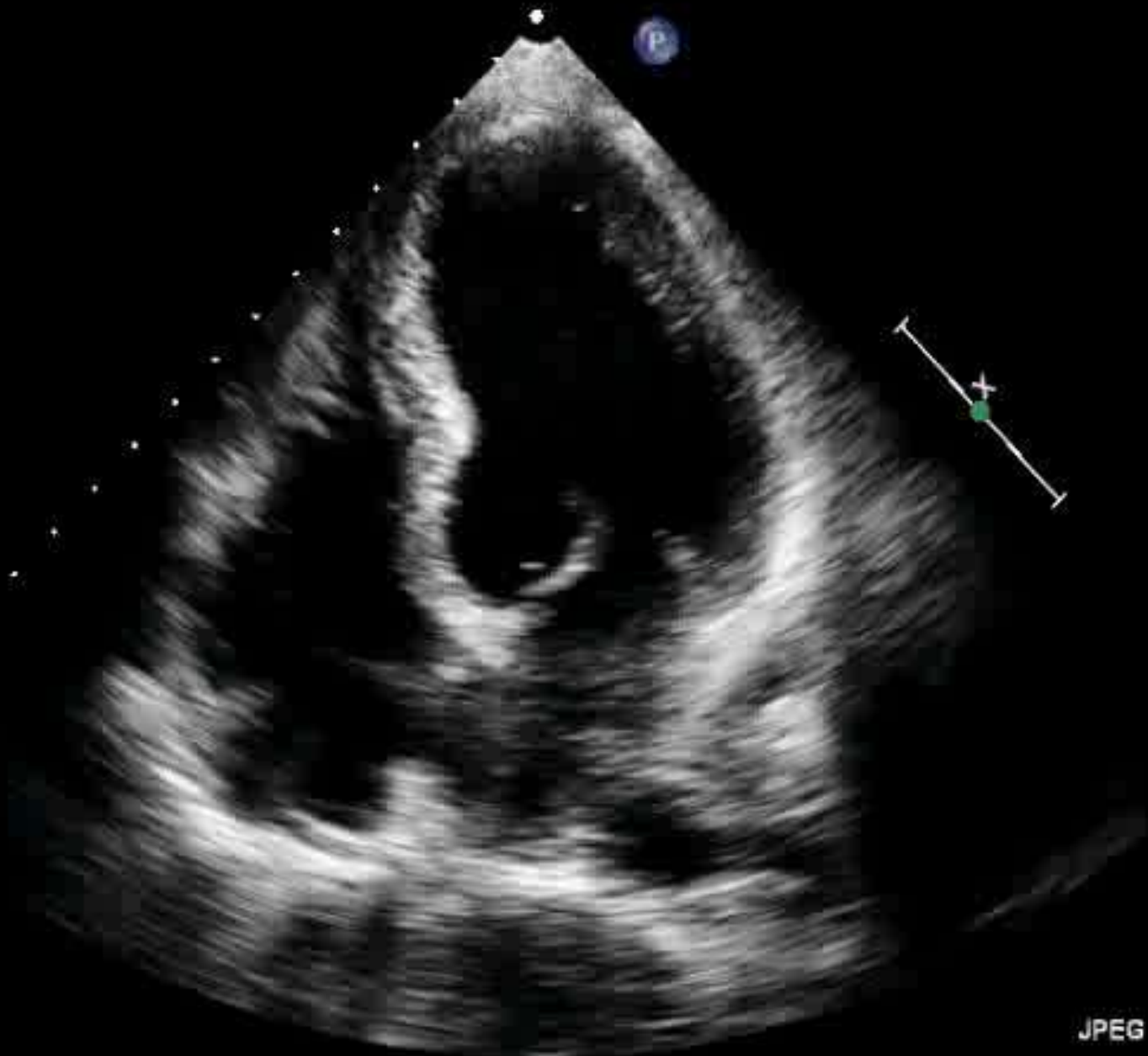
Ventricular angiography



PR 35HZ
17cm

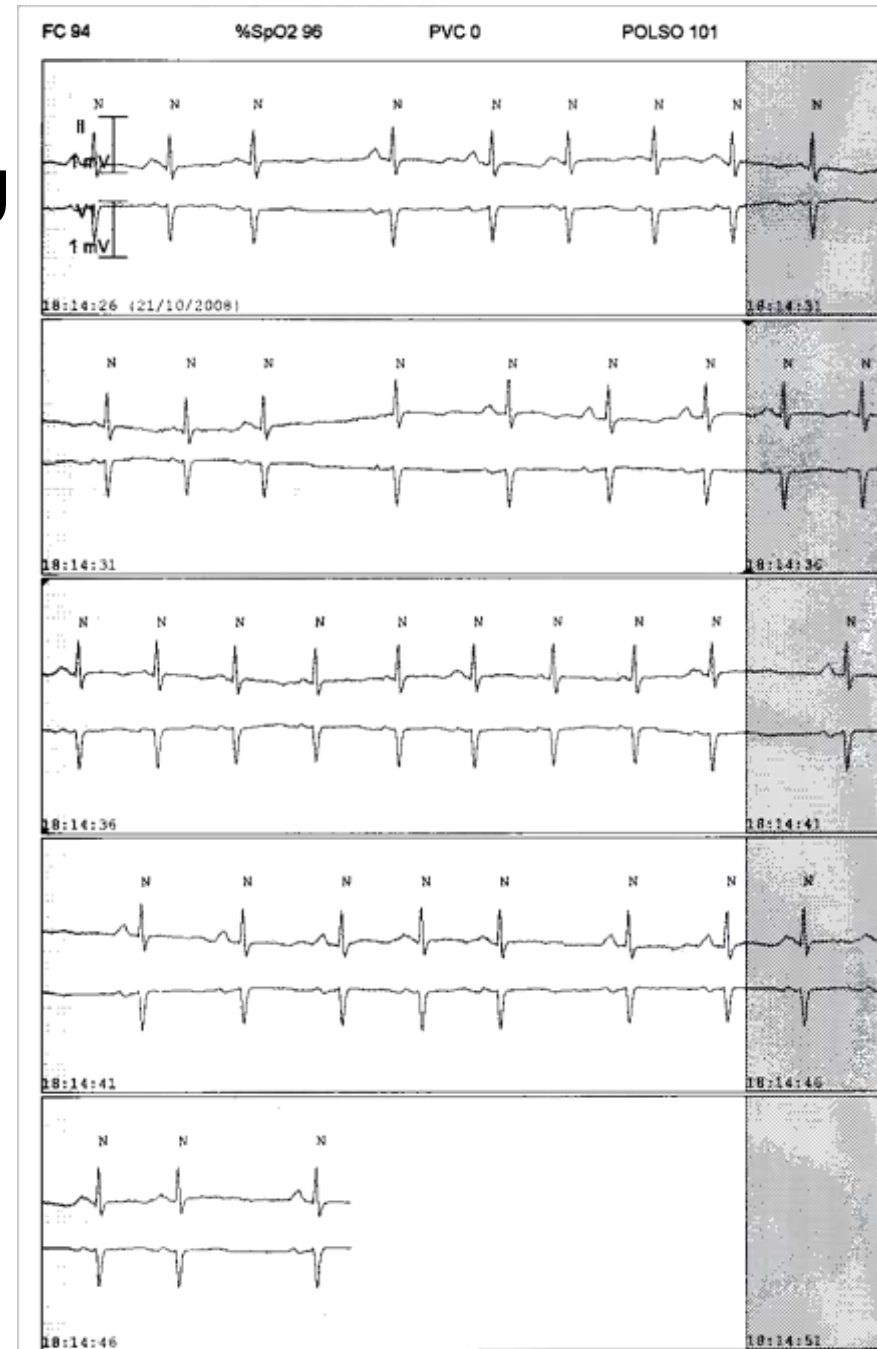
2D
65%
C 50
P Med.
APen



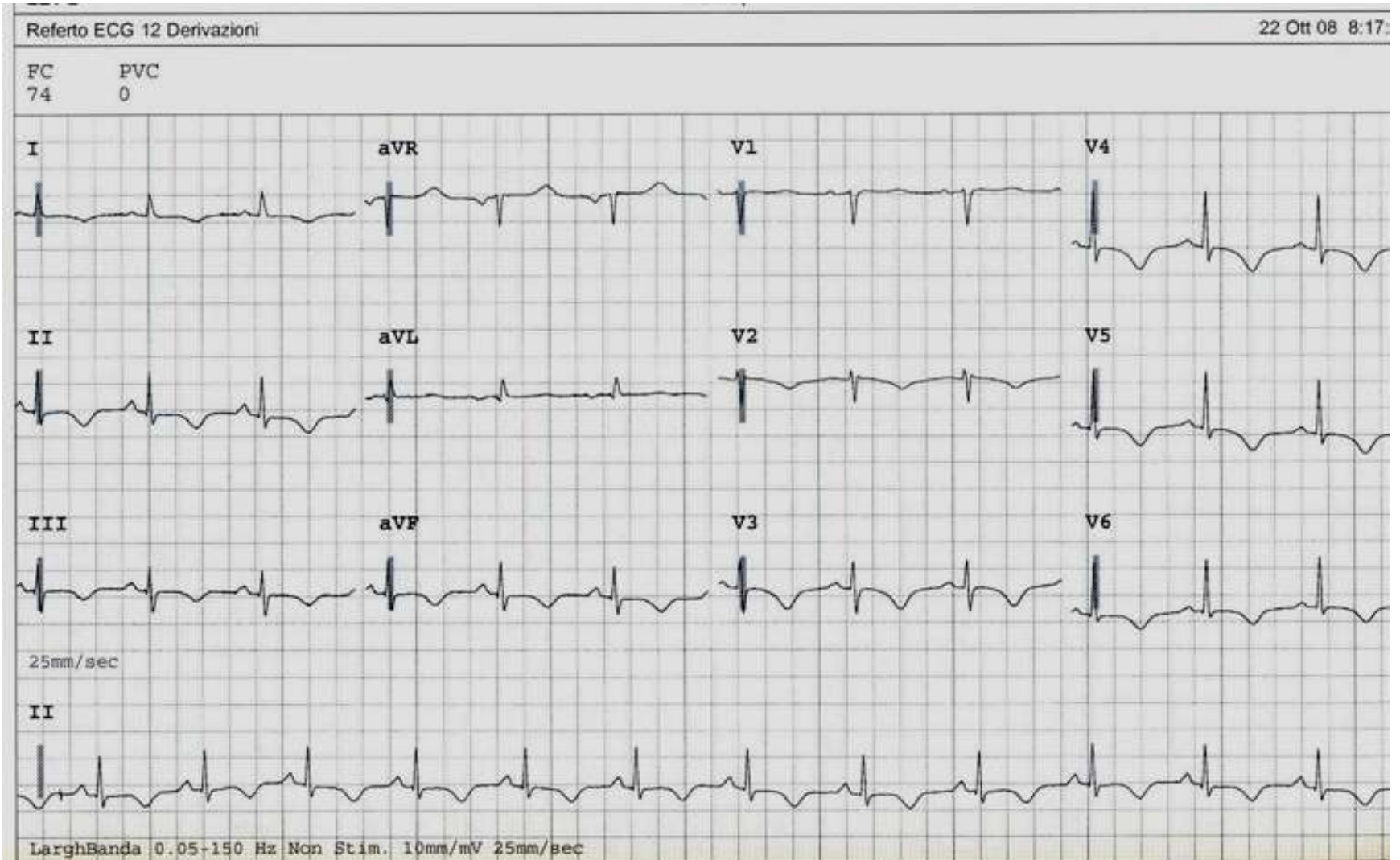
JPEG

- She was admitted in the ICU
- No symptoms
- BP 100/70 HR 90/m'

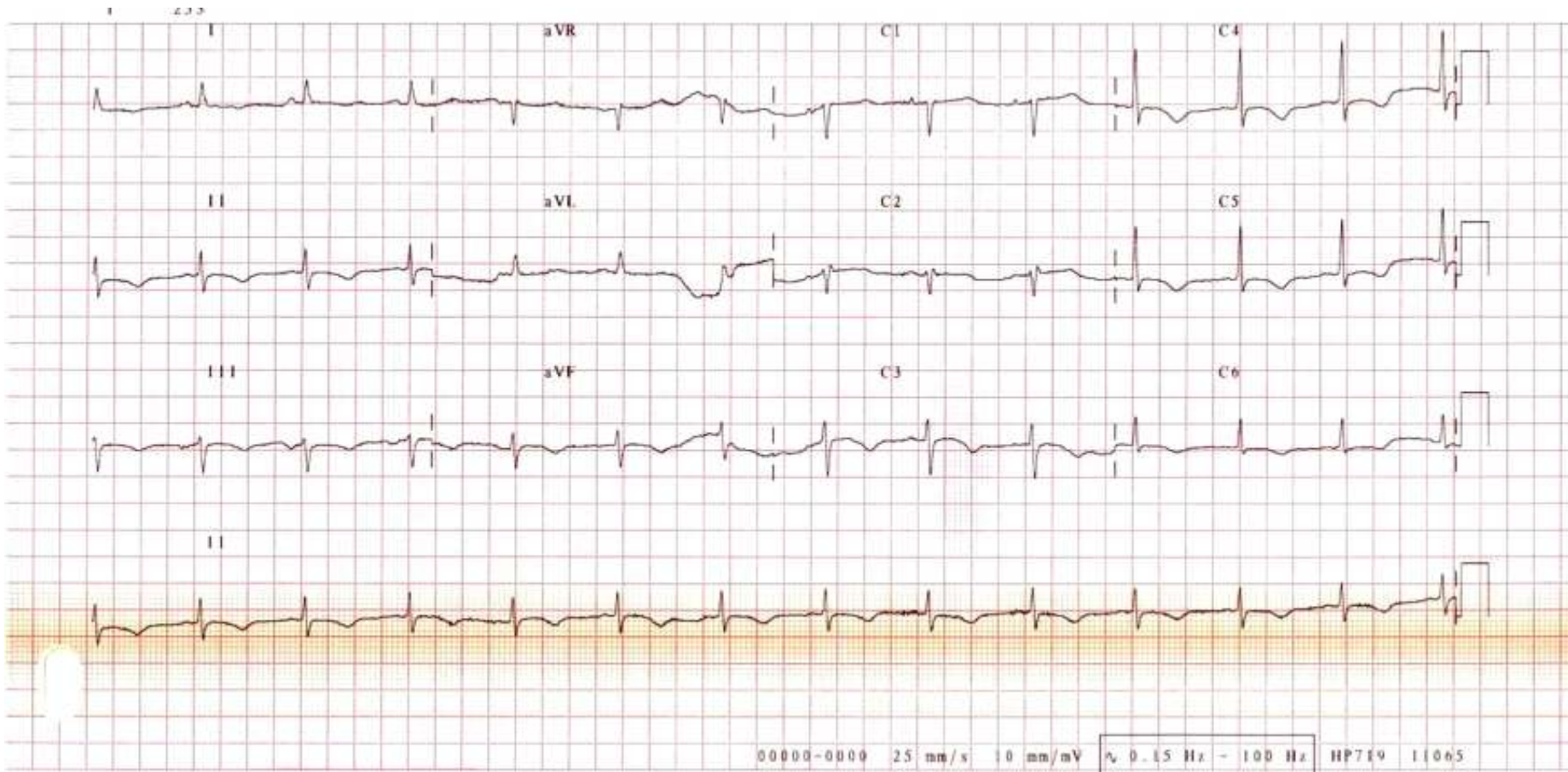
- During the first night →



EKG 22/10



ECG 23/10

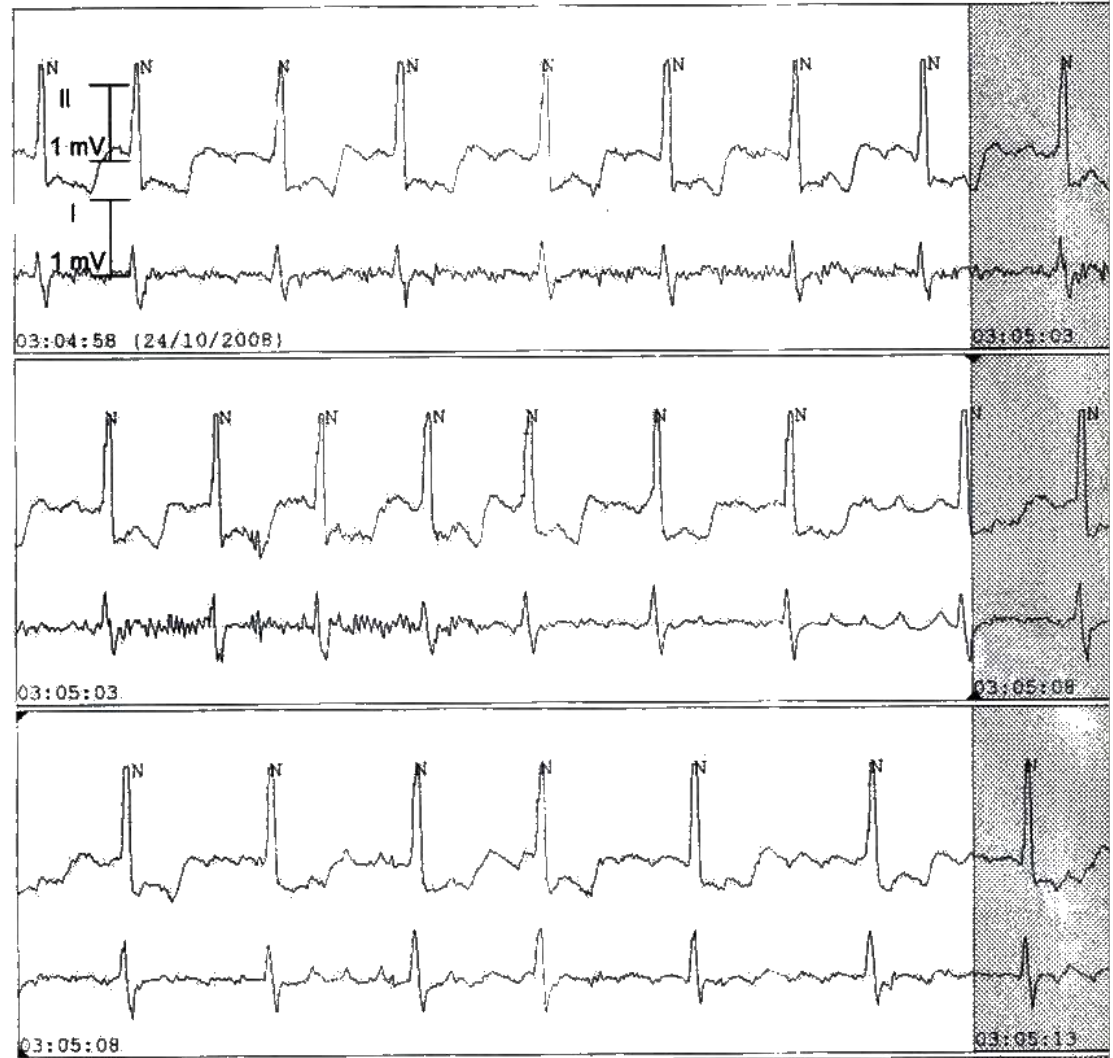
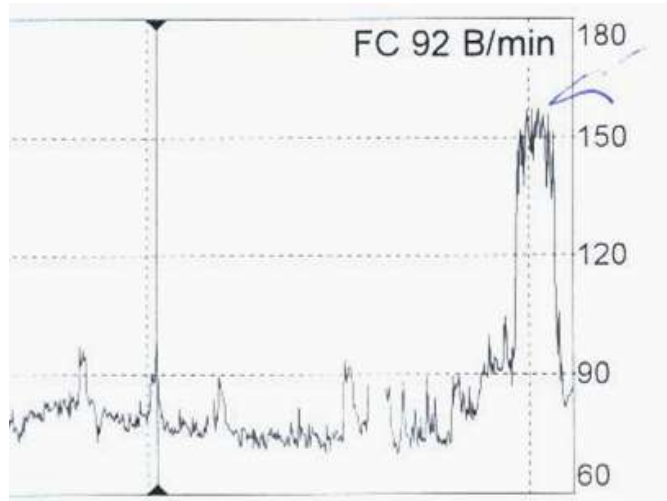


Monitor 24/10

Ref. Tracc. BODO 24/10/2008 03:05:08

FC 89

PVC 0



Diagnosis ?

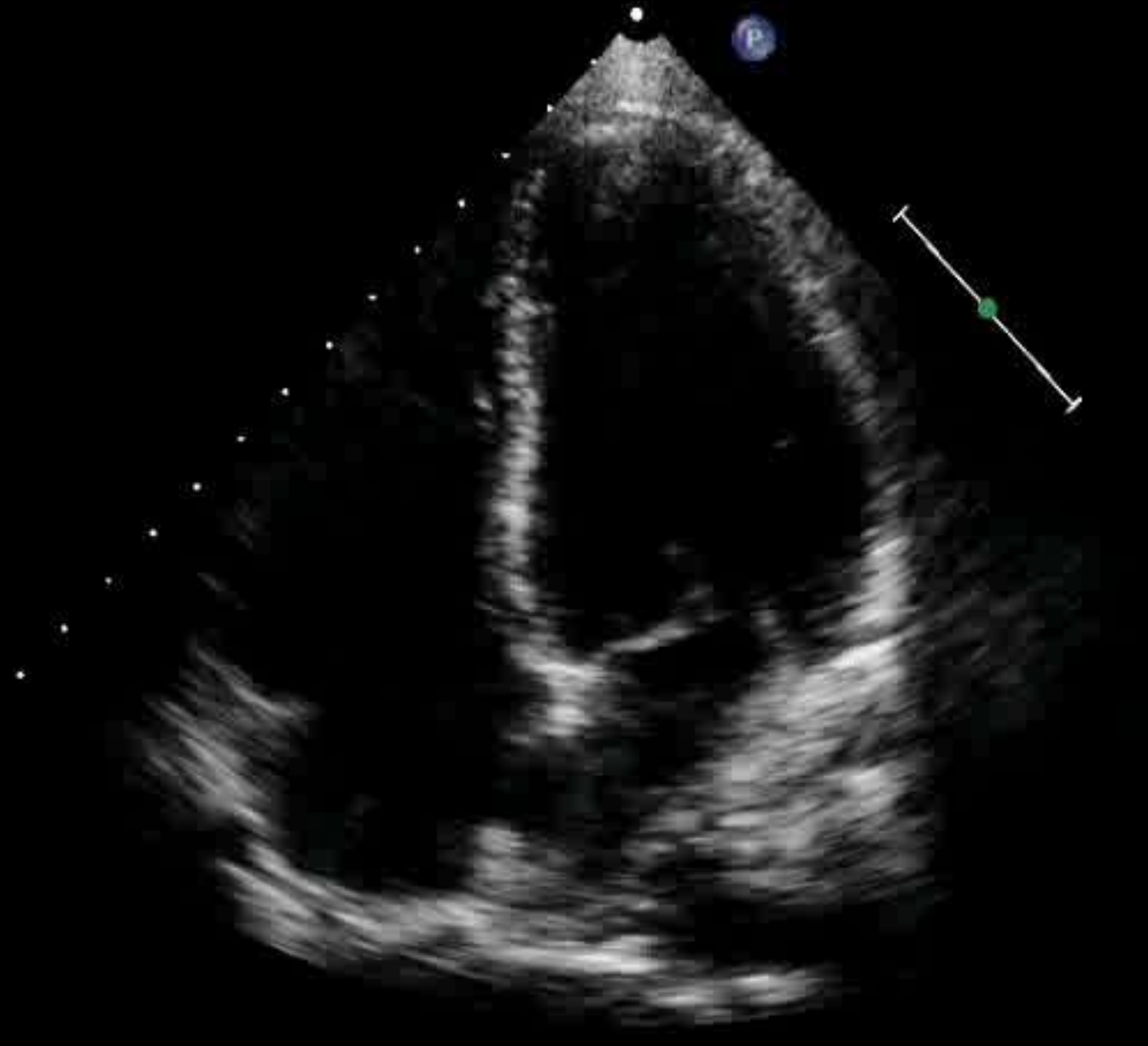
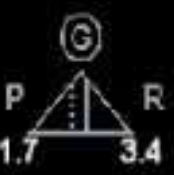- **Normal coronary artery myocardial infarction**
- **Apical ballooning (Takotsubo syndrome)**
- **Embolic infarction (paroxysmic atrial fibrillation)**
- **Myocarditis**

Next step ?

Therapy ?

FR 50Hz
15cm

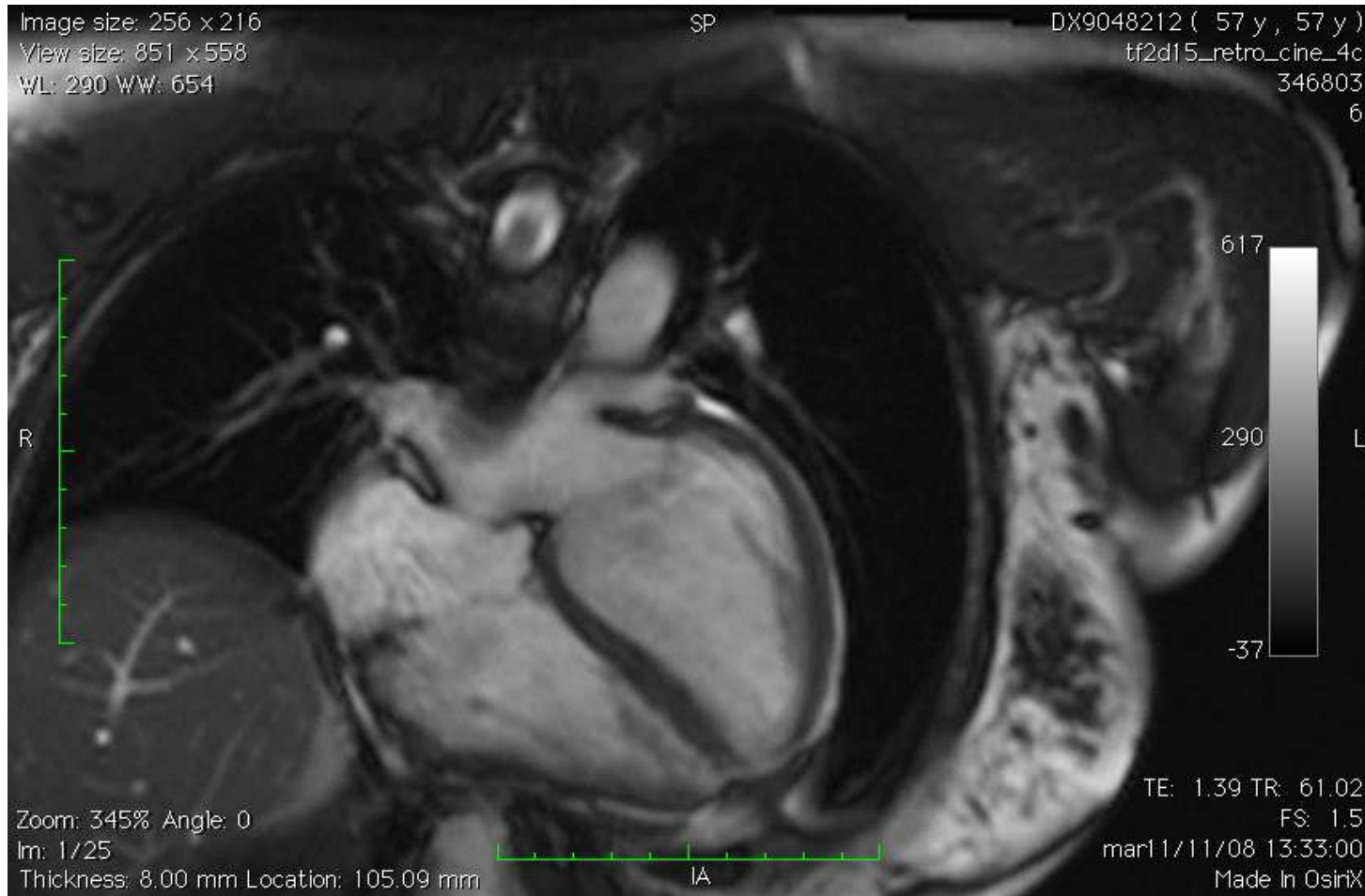
2D
55%
C 50
P Bassa
AGen



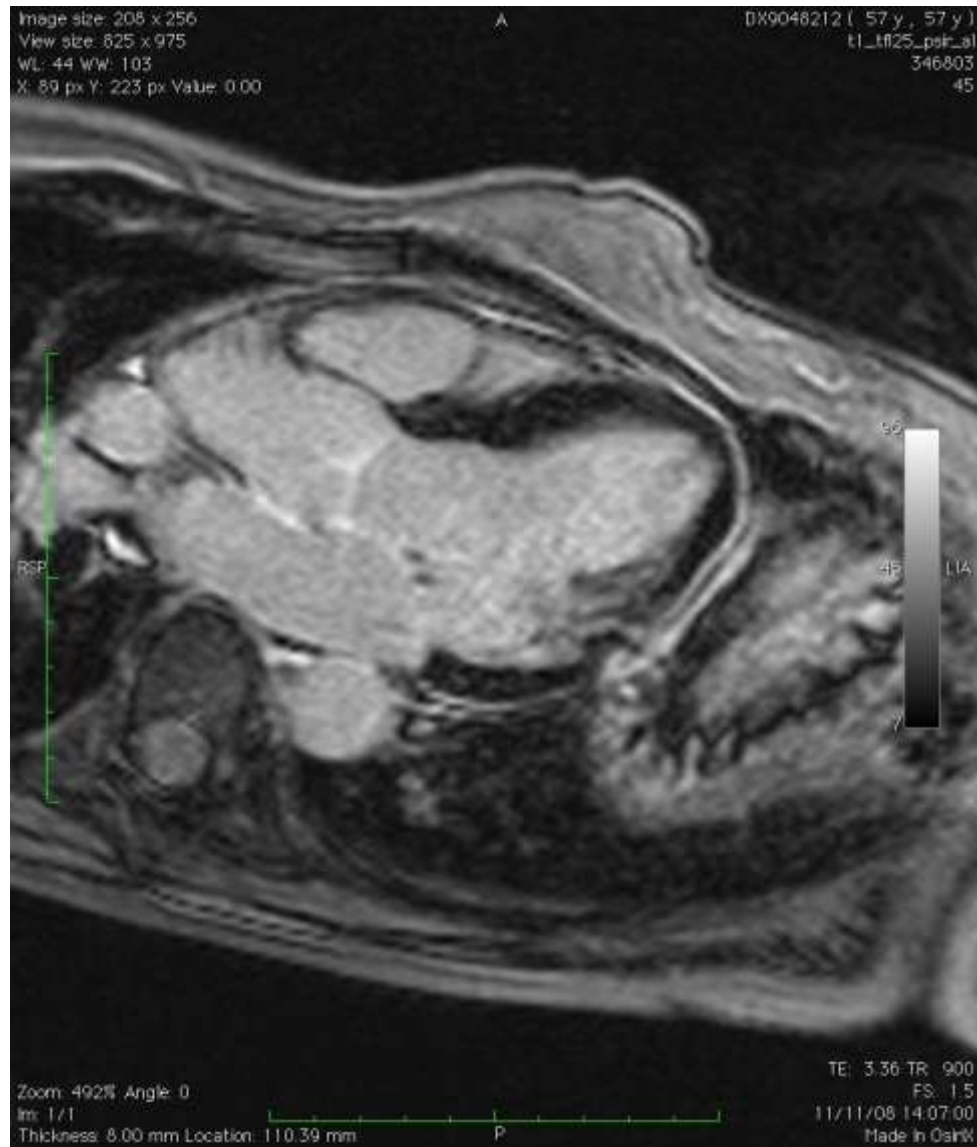
JPEG

54 bpm

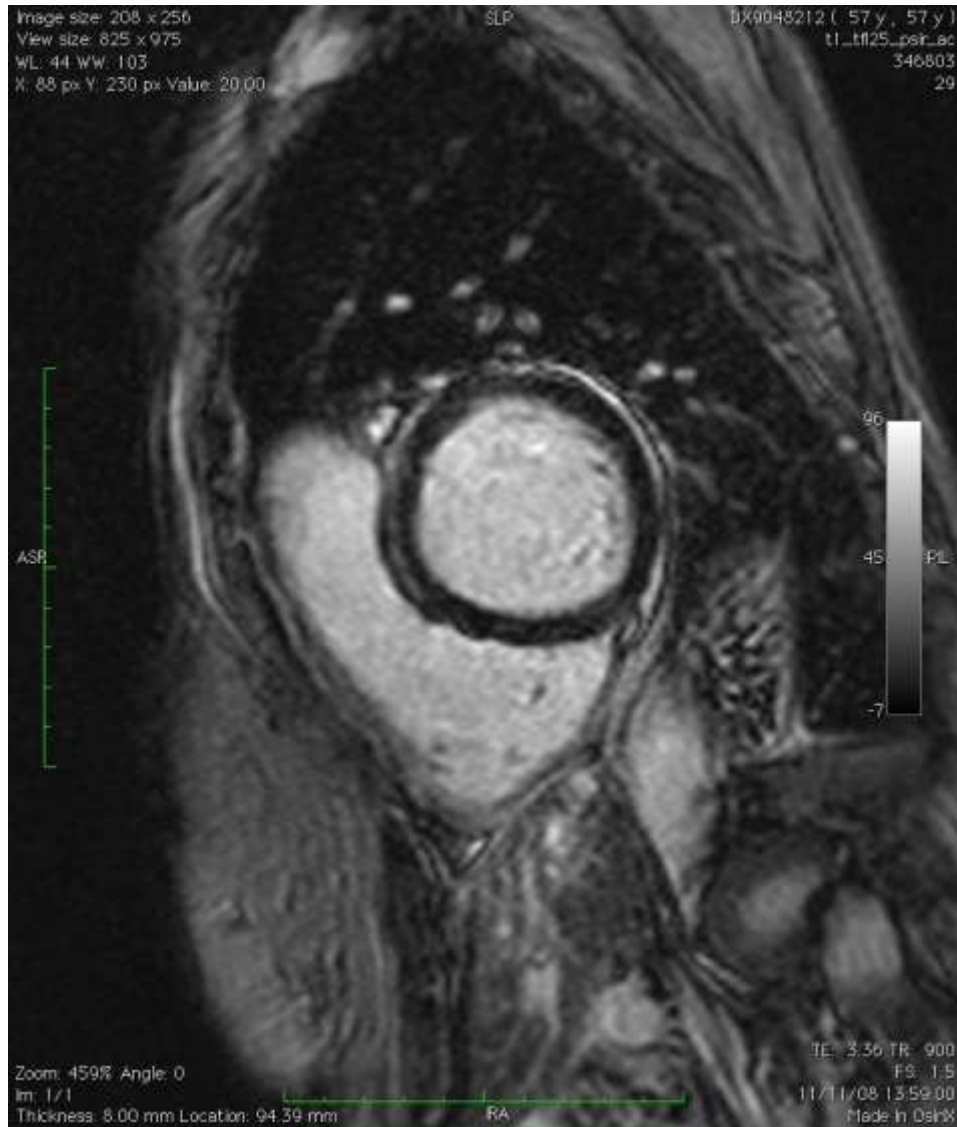
RMN 11/11



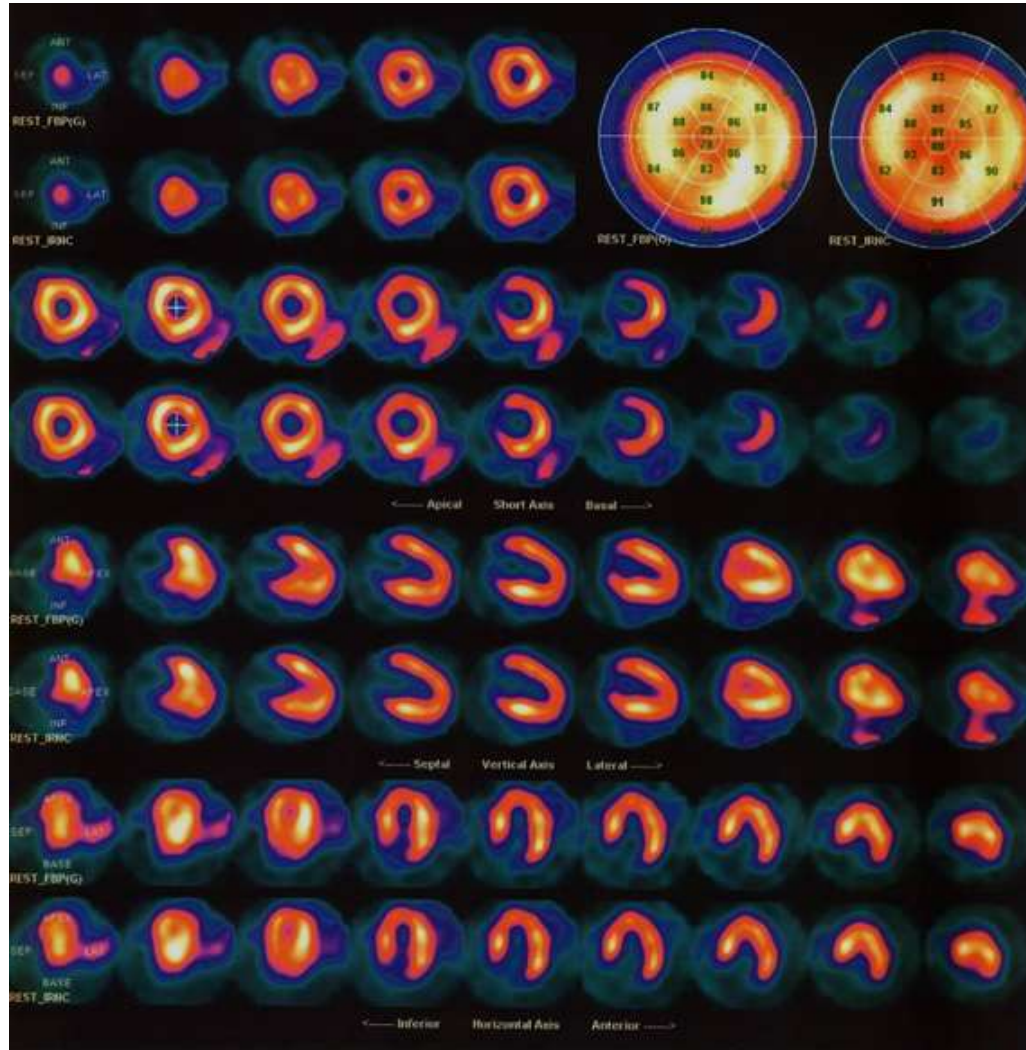
RMC



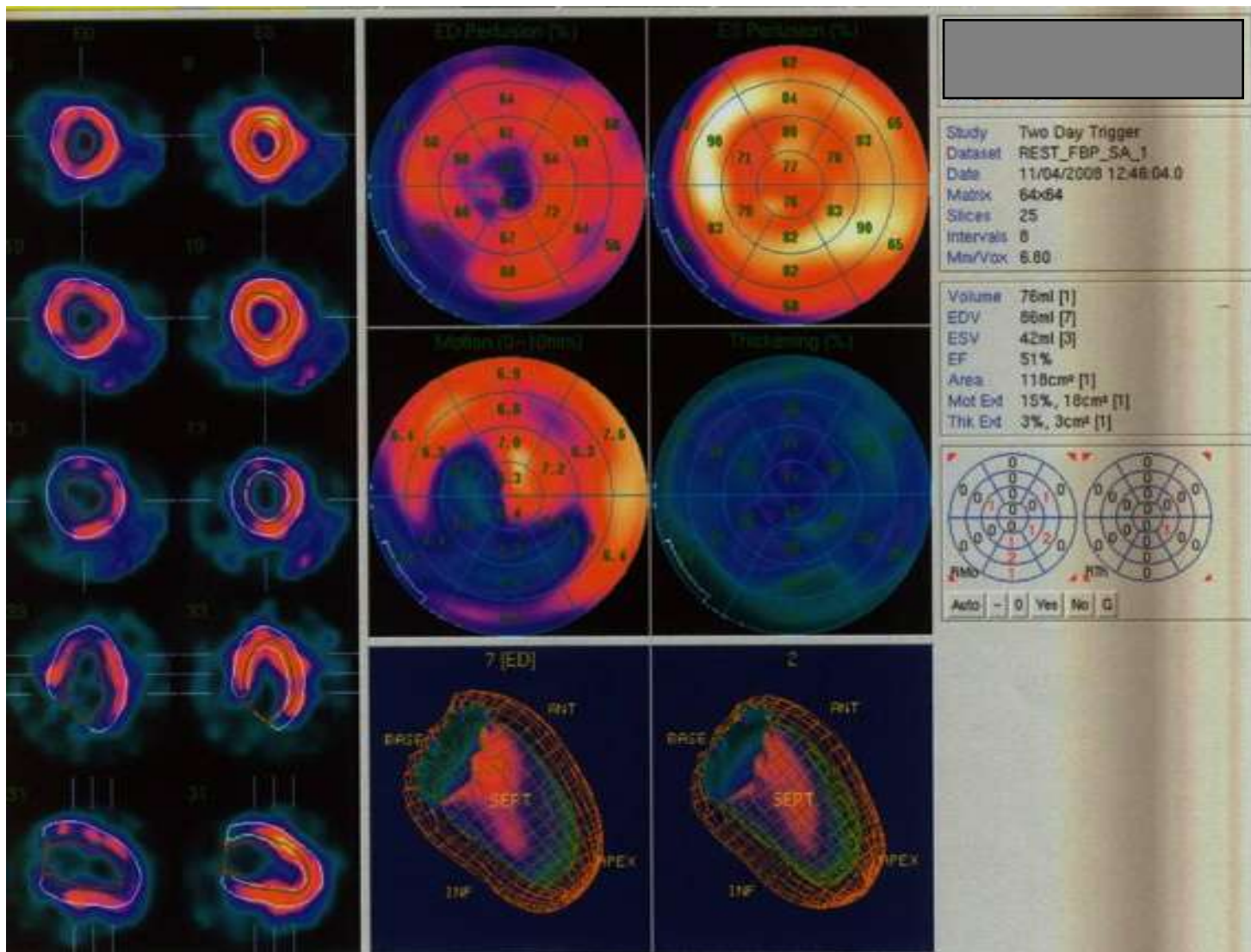
RMN 11/11



Tecnetium-99 m tetrofosmin myocardial SPECT 4/11



Tecnetium-99 m tetrofosmin myocardial SPECT 4/11



Therapy:

- Warfarin
- Carvedilol 12.5 X 2
- Ramipril
- Amiodarone 200 mg